

Clear margins for invasive lobular carcinoma: A surgical challenge

R.A. Sakr*, B. Poulet, G.J. Kaufman, C. Nos, K.B. Clough

Department of Breast Cancer and Reconstructive Surgery, Paris Breast Center, Paris, France

Accepted 6 January 2011

Available online 1 February 2011

Abstract

Background: The main goal of breast conservative surgery (BCS) is the complete removal of cancer with clear margins and no deformity of the breast. However, in invasive lobular carcinoma (ILC) this goal is hard to achieve because of the underestimation of tumor size. Our study was the first to show the role of surgical techniques in the achievement of clear margins for ILC.

Methods: We reviewed 73 patients with ILC who underwent BCS at Paris Breast Center between January 2005 and June 2008. Full thickness excision (FTE) was performed in a routine basis and oncoplastic surgery (OPS) upon tumor location, volume ratio and overall density of the breast. Margin status was evaluated as positive, close or clear.

Results: Positive/close margins were found in 39% of cases and were lower than what was described in the literature (49–63%). FTE was performed in 47 (64%) patients and OPS in 26 (36%) patients. No positive/close margins were observed in patients with lesions located in the lower/central quadrants. Multivariate analysis showed multifocality, larger tumor size and FTE to be independent risk factors for positive margins at final surgery.

Conclusions: Our rate of positive/close margins for ILC was lower than what was described in the literature. The determinant key difference was in our surgical procedures with FTE or OPS differing from the standard BCS described in the literature and we suggest that OPS is to be considered for ILC. It allows larger breast conservative surgery with good cosmetic results and lower rate of compromised margins.

© 2011 Elsevier Ltd. All rights reserved.

Keywords: Invasive lobular carcinoma; Oncoplastic surgery; Margins

Introduction

The main goal of breast conservative surgery (BCS) is the complete removal of cancer with clear surgical margins while maintaining the natural shape of the breast. In BCS for invasive lobular carcinoma (ILC) the primary goal of complete cancer removal with adequate surgical margins is hard to achieve compared to BCS for invasive ductal carcinoma (IDC). Historically, ILC accounts for 10% of invasive breast cancers and patients undergoing BCS for ILC frequently have higher rates of involved margins often in excess of 50%.^{1,2} Therefore the challenge in obtaining negative margins is partly due to the underestimation of tumor size with standard imaging modalities during preoperative surgical planning. This underestimation of size by both mammography or ultrasound evaluation is known to be mainly due to the lack of a desmoplastic reaction for ILC and preoperative

assessment with magnetic resonance imaging (MRI) have shown improvement in size estimation.^{3–5}

Series has demonstrated the difficulty to achieve negative margins after BCS for ILC and a reliable surgical solution regarding the limited success of BCS for ILC has not been developed.^{1,6,7} Few reports were extensively exploring intra-operative strategies for reducing rates of re-excision in both invasive ductal carcinoma (IDC) and ductal carcinoma in situ (DCIS) but similar studies for patients with ILC are limited in scope.⁸ More recently, reports have shown that oncoplastic surgery (OPS) was effective in reducing re-excision rate for positive margins in IDC and DCIS.^{9,10} OPS is defined by the combination of surgical oncology principles with plastic surgery techniques allowing larger excision of breast tissue compared to standard BCS.¹¹ It has resulted in the successful treatment of patients with DCIS and IDC, and our study is the first to evaluate the effectiveness of surgical techniques including OPS in ILC.

We reviewed patients with ILC undergoing BCS at Paris Breast Center and found a lower rate of involved margins (39%) compared to previous studies.^{1,6,7} Our aim was to

* Corresponding author. Paris Breast Center, 7 avenue Bugeaud, 75016 Paris, France. Tel.: +1 646 888 2472; fax: +1 646 888 3200.

E-mail address: ritasakr@yahoo.com (R.A. Sakr).

explore the role of surgical techniques in the achievement of clear margins for ILC.

Patients and methods

Patient selection

Seventy-three patients with ILC who underwent BCS at Paris Breast Center between 2005 and 2008 were included in the study with the approval of the center institutional committee. Selection criteria for conservative treatment included T1–T2 breast cancer as well as patient desire of breast conservation. Contraindications to BCS were multicentricity, recurrence or prior chest radiotherapy and neoadjuvant chemotherapy. In addition to preoperative clinical and mammographic evaluation, all patients had a biopsy-proven diagnosis and were operated by the same surgeons with dual training in surgical oncology and oncoplastic breast surgery. Patient's characteristics are described in Table 1.

Surgical technique

Before surgery, preoperative skin markings were completed with the patient in the upright position. For the non-palpable lesions either radio-guided localization with a hooked wire

or ultrasound-guided skin marking was performed. Skin incision was cosmetically placed following Langer's or Kraissl's lines. Surgical planning took into consideration the tumor location in the breast, the tumor-to-breast volume ratio and the overall density of the breast. It was classified as either full thickness excision (FTE) or level 1 and 2 oncoplastic surgery (OPS) as previously described in Clough et al.¹¹ FTE is based on dual-plane undermining without any skin excision while OPS involves skin excision and mammoplastic reshaping procedures derived from breast reduction techniques (Fig. 1).

In all procedures, the tissue was dissected down to the pectoralis fascia creating a full thickness one-bloc large resection. The tumor and the surrounding breast tissue were undermined off the pectoralis muscle allowing for bimanual palpation to center the excision around the tumor and grossly evaluate margin clearance. Undermining the breast also allowed for closure of the excision defect. This posterior dissection was sufficiently performed for appropriate reshaping and closing of remaining breast gland. Care has been taken to avoid major vascular perforators and collateral blood supply reducing the risk of glandular necrosis. After appropriate mobilization of fibroglandular tissue, surgical margins of the resection cavity were marked with radiopaque clips to facilitate planning for radiation. If re-excision was needed, the performed procedure was a wide local excision or a salvage mastectomy.

Sentinel lymph node biopsy and/or axillary lymph node dissection were performed through a separate axillary incision or an extension of radial upper outer incisions. All patients completing BCS had adjuvant radiotherapy and were evaluated by the medical oncology team for appropriate adjuvant therapy. Postoperative follow-up was scheduled every 3 months for the first year and annually thereafter.

Specimen evaluation

After placement of orientation sutures, all surgical specimens were grossly examined jointly by both the surgeon and the pathologist, with a specimen radiograph for non-palpable lesions. If required, close margins identified by the surgeon on palpation or by the pathologist on gross examination were followed by immediate re-excision. Tumor size was defined as the largest dimension recorded by the pathologist and margins were measured as the distance of the tumor to the edge of the resected specimen. Margin status was considered positive if invasive carcinoma was found at ink on the edge of resected specimen and within 1 mm; or close if it was <2 mm on final histologic review. Re-excision was therefore performed for positive/close margins except for cases where it was not feasible. All clear margins were re-reviewed for the purpose of this study and found to be >5 mm, thus considered the clear margins limit in the study.

Statistical analysis

We performed univariate (chi-square or Fisher's exact test and *t*-test) and multivariate (logistic regression model)

Table 1
Univariate analysis of the 73 patients with BCS and ILC.

Characteristic	Negative margins (N = 44)	Close/positive margins (N = 29)	<i>p</i> -value
Mean age (years, range)	59 (41–76)	55 (37–74)	<0.039
Post-menopausal status (n,%)	33 (75)	19 (65)	ns
Familial history of breast cancer (n)	10 (23)	3 (10)	ns
History of HRT (n)	8 (18)	2 (7)	ns
Tumor imaging size (mean, mm)	13 (4–30)	13 (4–20)	ns
Palpable mass (n)	26 (59)	18 (62)	ns
Specimen resection size (mean, mm)	63 (30–110)	60 (30–90)	ns
Tumor histology size (mean, mm)	15 (2–47)	23 (10–50)	0.002
Tumor stage			0.006
T1 (n)	33 (75)	12 (41)	
T2 (n)	11 (25)	17 (59)	
Multifocality (n)	7 (16)	24 (83)	0.000
Grade 1/2 (n)	40 (91)	28 (96)	ns
Low mitotic index (n)	35 (79)	22 (76)	ns
ER positive (n)	43 (98)	27 (93)	ns
PR positive (n)	31 (70)	23 (79)	ns
Tumor location			
Upper outer	22 (50)	14 (48)	ns
Upper inner	10 (23)	15 (52)	0.013
Lower	10 (23)	0	–
Central	2 (5)	0	–
Surgery type			0.045
FTE	24 (55)	23 (79)	
OPS	20 (45)	6 (21)	

BCS: breast conservative surgery; ILC: invasive lobular carcinoma; HRT: hormonal replacement therapy.

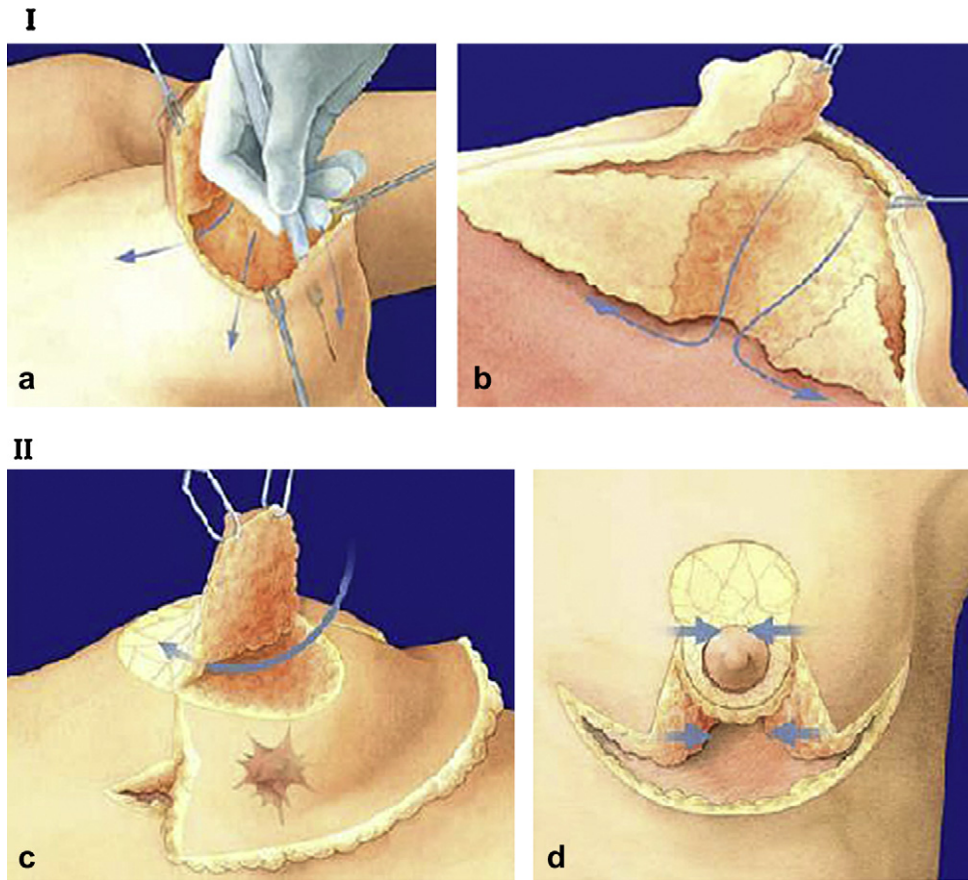


Figure 1. I. Full thickness excision and oncoplastic surgery level 1. a: Initial skin undermining; b: Full thickness excision of the lesion from the subcutaneous tissue to the pectoralis fascia.¹¹ II. Oncoplastic surgery level 2. c: Superior pedicle deepithelialization and elevation; d: Re-approximation of medial and lateral glandular flaps after wide excision.¹¹

analyses to explore factors associated with positive/close margins. *P*-value <0.05 signified a statistically significant difference.

Results

A total of 73 patients with ILC treated with BCS were included in the study. The median patient age was 58 years (range 37–76 years). Margins were clear in 44 cases, close in 10 cases and positive in 19 cases. A second re-excision was performed in 17 patients with positive/close margins: 12 patients had mastectomy and residual carcinoma was found in 9 patients.

Preoperative planning

All 73 patients underwent a preoperative mammography and ultrasound evaluation, then a core biopsy diagnosis of ILC prior to surgery. MRI was available for only 11 patients at preoperative evaluation (Table 1) with FTE performed in 5 cases and OPS in 6 cases. Patients younger than 50 years had involved margins rate of 56% versus 35% in the patients older than 50 years. Among the 44 patients with palpable lesion, 18 patients had involved margins compared to 11 among the 29 patients with non-palpable lesions. Of those

who had measurable lesions, the median mammographic and ultrasound size was 12 mm (range 4–30 mm).

Surgical resection

The median size of resected tissue was 60 mm (range 30–110 mm). On final pathology examination, the median histologic size (16 mm) was significantly larger than the median mammographic size (12 mm). Multifocality was found in 33 patients and axillary lymph node positivity in 26 patients. Biological markers were also available for the 73 patients (Table 1). The final histologic margins assessment resulted in 19 patients with margins inferior to 1 mm (positive) on final histology, 10 patients with margins inferior to 2 mm (close), and 44 patients with margins more than 5 mm (clear). The median resected specimen size of the 29 cases with positive/close margins, was 60 mm (range 30–90 mm). Their median histology size (16 mm) was also significantly higher than the median preoperative mammographic size (12 mm).

Margins status by surgical procedure

FTE was performed in 47 (64%) patients and OPS in 26 (36%) patients. The rate of involved margins was described

relative to tumor location in the breast and to surgical procedure (Fig. 2). No positive/close margins were observed in patients with lesions located in the lower/central quadrants, and level 2 OPS was the performed procedure in all these cases. Specimen size ranged from 40 mm to 110 mm in the lower quadrant tumors and from 40 mm to 50 mm for central tumors. Of the patients with upper outer quadrant lesions, 14 patients had positive/close margins with level 2 OPS performed in only 9 cases. In the upper inner locations, 15 patients had positive/close margins with a mean specimen size of 60 mm and level 1 OPS performed in only 5 cases.

Risk factors for positive margins

The correlation between patient’s characteristics and margins positivity is reported in Table 1. Patients with positive/close margins were significantly younger than patients with negative margins ($p < 0.039$). Tumors with positive/close margins were found to be significantly larger, more multifocal and more common in upper inner quadrants than tumors with negative margins ($p = 0.002, <0.001$ and 0.013 , respectively). They were significantly less pronounced when OPS was the performed surgery ($p = 0.045$). On multivariate analysis, both multifocality and larger size showed to be strong independent risk factors for margins positivity ($p < 0.00001$ and 0.0095 respectively) (Table 2). Compared to OPS, performing FTE was also found to be an independent risk factor for clear margins failure ($p = 0.039$).

Discussion

Alternative surgery for ILC

Through differing surgical techniques, BCS can be safely considered for ILC in spite of earlier concerns and failures. Studies that addressed BCS in ILC were either suggesting that it was a good alternative for mastectomy or expressing reservation regarding the lack of surrounding desmoplastic reaction.^{12–15} Although there have been studies with long follow-up after BCS reporting similar outcome in terms of local recurrence and survival for ILC as for IDC, this is the first study that evaluates new non-standard BCS including OPS for ILC.^{1,3,16–20} The introduction of OPS as an alternative for standard BCS has proven to be effective for tumors located in regions of the breast at risk of deformity. OPS previously described as a “third pathway” for patients with breast cancer was shown to reduce re-excision rate for positive margins, thus preserving the natural shape of the breast.⁹ Recent studies have described OPS as a strategy for BCS after neoadjuvant chemotherapy and for BCS of DCIS.^{10,21} Our series is the first description of a non-standard BCS and OPS for ILC, resulting in avoidance of deformity and reduction in the rate of involved margins. The lower rate of positive/close margins in our study (39%) compared to previous studies is directly related to our surgical technique as all our patients underwent either FTE or OPS which are different from standard BCS of the published series (Table 3).

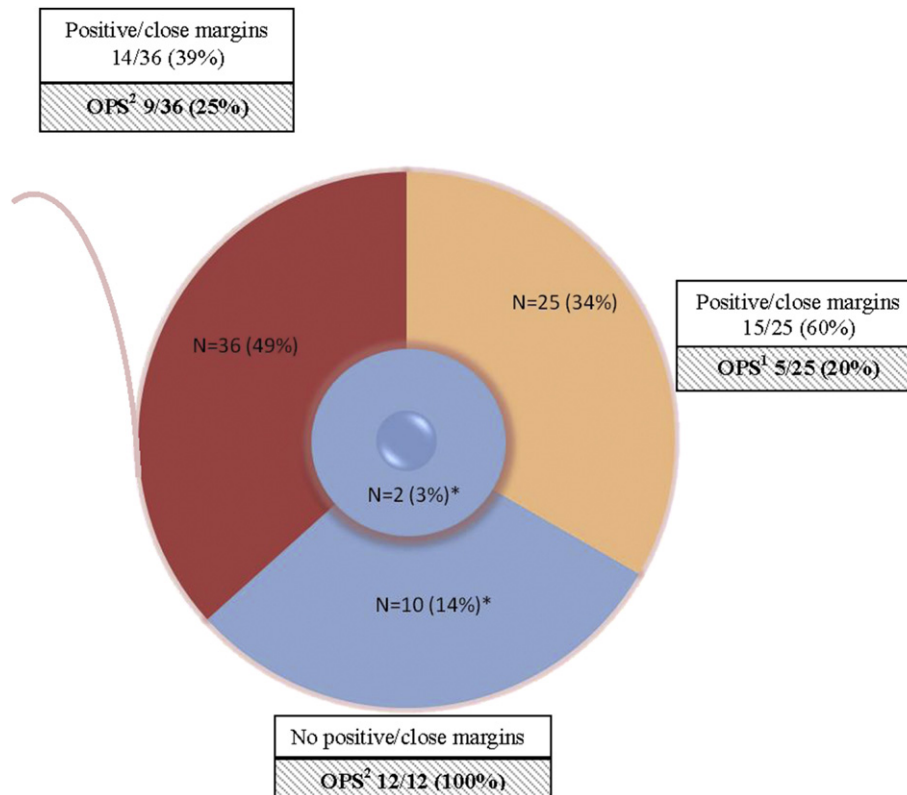


Figure 2. Positive/close margins by tumor location and surgery. * No compromised margins nor re-excision in lower and central locations (100% OPS). OPS²: oncoplastic surgery level 2; OPS¹: oncoplastic surgery level 1; BCS: breast conservative surgery; ILC: invasive lobular carcinoma.

Table 2
Multivariate analysis of the identified risk factors of positive/close margins in patients with BCS and ILC.

Characteristic	Negative margins (N = 44)	Close/positive margins (N = 29)	p-value	Multivariate analysis	
				OR	p-value
Mean age (years, range)	59 (41–76)	55 (37–74)	<0.039	–	ns
Mean histology size (mm, range)	15 (2–47)	23 (10–50)	0.002	1.10[1.02–1.17]	0.0095
Stage T2 (n,%)	11 (25)	17 (59)	0.006	–	ns
Multifocality (n,%)	7 (16)	24 (83)	0.000	19.1[4.83–75.5]	<0.00001
Upper inner location (n,%)	10 (23)	15 (52)	0.013	–	ns
FTE surgery (n,%)	24 (55)	23 (79)	0.045	4.57[1.08–19.4]	0.039

BCS: breast conservative surgery; ILC: invasive lobular carcinoma; FTE: full thickness excision.

Preoperative evaluation

An important component of successful BCS is preoperative evaluation but detection of ILC by mammography is not as accurate as preoperative imaging for IDC.^{22,23} The limitation in accurate preoperative size evaluation for ILC is due to the lack of strong desmoplastic reaction seen with IDC and results in final size underestimation when compared to pathological specimen review.^{16,24} In our study, we found a significant preoperative underestimation of lesion size by standard imaging modalities. The mean preoperative mammographic size was significantly smaller compared to a mean final histology size (13 mm vs 18 mm; $p = 0.0007$). It was also significantly smaller in the patients who required re-excision for positive/close margins where the lesion histology size was greater than 25 mm ($p = 0.0031$). Therefore systematic preoperative surgical planning seems to be of great value to compensate the consisting size underestimation. We believe that adherence to principles of surgery selection and procedure choice based on FTE and OPS over standard BCS allows larger excision volume with lower risk of both size underestimation and deformity.^{9,11}

Surgery

Increasing use of diagnostic biopsy allowed a better evaluation and facilitated planning for single-stage BCS. Consequently, when ILC was diagnosed on core biopsy, it could help decision toward a more tailored surgery instead of the standard surgical approach described in the literature. The advantage of OPS and FTE resides in the potential to eliminate the need for re-excision through large volume excision

compared to standard BCS. Although multiple re-excisions do not impact long-term recurrence and overall survival results, the physical and psychological burden placed on the patient to return to the operating room after the initial surgery can influence a patient’s decision in choosing mastectomy over BCS.²⁵ FTE and OPS can also reduce the risk of cosmetic sequelae when the ratio of excision volume-to-breast size exceeds 20%. Breast deformity after BCS that is not recognized prior to radiation treatment can only be corrected by volume replacement techniques. However, the utilization of these techniques to correct breast deformity eliminates a major reconstructive option if mastectomy is required for recurrence. The goal of OPS is to avoid deformity through preoperative decision making regarding the best possible oncological procedure and then through a redistribution of the remaining breast tissue. The redistribution can be achieved either through level 1 approach that involves advancement or rotation of gland to fill excision defects or through level 2 procedure with excision of both breast tissue and overlying skin to form a new breast shape. In our study, surgical procedure differed from traditional BCS performed in the studies described in Table 3. Landmarks for surgical planning were marked preoperatively in standing position, thereby allowing to anticipate removal of wide tumor. Then full thickness en-bloc tumor-bearing tissue resection and OPS level 1 or level 2 were performed according to the required procedure and followed by remodeling of glandular flaps according to the performed technique. A certain limitation of our study by the retrospective design and the comparison to literature reports has to be underlined. However by taking into account the frequency of T1/T2 lesions and the clear margins limit in each of the published series, our rate of positive/close margins was interestingly lower (39%) compared to what was already described for ILC (49–63%). Furthermore, with a mean resected tissue size of 61 mm, all the patients in our study showed a good cosmetic result at one year follow-up.

Table 3
Margins status after BCS for ILC: published data.

Author	Positive/close margins	Clear margins limit (mm)	T1–T2
White et al. (1994) ¹	63% (19/30)	2	66–7%
Silverstein et al. (1994) ⁶	59% (96/161)	1	41–49%
Moore et al. (2000) ⁷	51% (24/47)	2	42–58%
Hussien et al. (2003) ¹²	63% (34/54)	5	78–14%
Takehara et al. (2004) ²	60% (15/25)	–	–
Dillon et al. (2006) ²⁴	49% (38/77)	5	–
(Our study)	39% (29/73)	5	62–38%

BCS: breast conservative surgery; ILC: invasive lobular carcinoma.

Risk factors for margins positivity

Lateral dissection of subcutaneous layer and remaining defect left to fill up with seroma in majority of traditional BCS as well as scooping out the tumor from the breast could be at the origin of the higher rate of involved margins and cosmetic sequelae. Our surgical approach for BCS

followed FTE technique that involves full thickness glandular excision from the subcutaneous fat to the pectoralis fascia or OPS techniques. Therefore, the resulting glandular defect is closed with re-approximation of the remaining breast tissue allowing to help removing large breast tumors from skin to muscle with clear margins and good cosmetic outcome. However, in spite of the larger size of the specimen, we found the tumor size on final pathology to be an independent risk factor of margins positivity (Table 2). Multifocality was even a stronger independent risk factor of margins positivity ($p < 0.00001$). This would strongly imply that underestimation of multifocality and size of the lesion on preoperative evaluation remains an issue in spite of wider surgery. Independently of multifocality and tumor size, the type of surgery was also found to be a significant risk factor for margins positivity with OPS being associated to a better chance for clear margins ($p = 0.039$). This may be supportive of the benefit of OPS to overcome the risk of underestimation of the size and multifocality without the need for additional evaluation. On the other hand, the difference observed with type of surgery but not with size of surgical specimen among patients with negative or close/positive margins could be explained by the benefit of the surgical technique performed in OPS compared to FTE. However further comparative studies are needed before drawing any conclusion.

Tumor location was another observed key in our study. When the lesion was located in the lower quadrant of the breast where good cosmetic outcome for large tumors is hard to obtain, margins were clear after level 2 OPS technique with a mean resected specimen size of 64 mm. Similarly, margins were clear in central locations and level 2 OPS was the performed procedure. In the upper outer location tumors, the rate of positive/close margins was 39% with a mean resected specimen size of 62 mm. Although not reaching statistical significance, when a level 2 OPS approach was used there was a considerable lower rate of positive/close margins as compared to FTE approach (22% vs 44%), pleading in favor of OPS in this location too. Finally, in the upper inner location tumors the rate of positive/close margins was the highest (60%), independently of the surgical procedure type with a mean resected specimen size of 60 mm. This could be explained by the surgical difficulties and limitations specific to this location. Upper inner wide excision could have serious distorting impact on the visible shape of the breast and level 2 OPS procedure that could reliably address these limitations is not established yet. Moreover, when we analyzed margins by type of surgery, performing FTE was found to be an independent risk factor of margins positivity, suggesting the big value of considering OPS for ILC lesions. However when the tumor is in the upper inner quadrant, limitations of extensive BCS even with OPS approach should be further discussed with the patient upon the planning of appropriate procedure. As for cosmetic results, all patients in our study had good results independently of tumor location and type of surgery, adding another plea in favor of FTE and

OPS for ILC tumors by allowing larger resection with good cosmetic outcome.

Conclusion

Obtaining clear margins could be difficult with ILC since resection of large and unlimited tumors needed more consideration and planning in order to remove the malignant tissue with adequate margins and good cosmetic result. While the management of ILC regarding breast conservation remains difficult because of the higher rate of involved margins and re-excision, our study revealed a lower rate of positive/close margins for ILC tumors than what was already described. Our surgical procedure with FTE or OPS was different from standard BCS, allowing large BCS with good cosmetic results and lower rate of involved margins. Further analysis showed multifocality and larger size of tumor to be independent risk factors for margins positivity. It also showed an independent benefit of OPS for clear margins in all tumor locations of ILC. Finally, FTE and OPS encompassed other important advantages including one-time surgery and avoiding delay of appropriate adjuvant therapy for ILC.

Acknowledgments

We would like to thank Pr Roman Rouzier for his assistance with the statistical analysis.

Conflict of interest statement

The authors have no conflict of interest to declare.

References

- White JR, Gustafson GS, Wimbish K, et al. Conservative surgery and radiation therapy for infiltrating lobular carcinoma of the breast. The role of preoperative mammograms in guiding treatment. *Cancer* 1994;**74**:640–7.
- Takehara M, Tamura M, Kameda H, Ogita M. Examination of breast conserving therapy in lobular carcinoma. *Breast Cancer* 2004;**11**:69–72.
- Holland PA, Shah A, Howell A, et al. Lobular carcinoma of the breast can be managed by breast-conserving therapy. *Br J Surg* 1995;**82**:1364–6.
- Mendelson EB, Harris KM, Doshi N, Tobon H. Infiltrating lobular carcinoma: mammographic patterns with pathologic correlation. *AJR Am J Roentgenol* 1989;**153**:265–71.
- Mann RM, Loo CE, Wobbes T, et al. The impact of preoperative breast MRI on the re-excision rate in invasive lobular carcinoma of the breast. *Breast Cancer Res Treat* 2010;**119**:415–22.
- Silverstein MJ, Lewinsky BS, Waisman JR, et al. Infiltrating lobular carcinoma. Is it different from infiltrating duct carcinoma? *Cancer* 1994;**73**:1673–7.
- Moore MM, Borossa G, Imbrie JZ, et al. Association of infiltrating lobular carcinoma with positive surgical margins after breast-conservation therapy. *Ann Surg* 2000;**231**:877–82.
- Cabioglu N, Hunt KK, Sahin AA, et al. Role for intraoperative margin assessment in patients undergoing breast-conserving surgery. *Ann Surg Oncol* 2007;**14**:1458–71.

9. Clough KB, Lewis JS, Couturaud B, et al. Oncoplastic techniques allow extensive resections for breast-conserving therapy of breast carcinomas. *Ann Surg* 2003;**237**:26–34.
10. Song HM, Styblo TM, Carlson GW, Losken A. The use of oncoplastic reduction techniques to reconstruct partial mastectomy defects in women with ductal carcinoma in situ. *Breast J* 2010;**16**:141–6.
11. Clough KB, Kaufman GJ, Nos C, et al. Improving breast cancer surgery: a classification and quadrant per quadrant atlas for oncoplastic surgery. *Ann Surg Oncol* 2010;**17**:1375–91.
12. Hussien M, Lioe TF, Finnegan J, Spence RA. Surgical treatment for invasive lobular carcinoma of the breast. *Breast* 2003;**12**:23–35.
13. Warneke J, Berger R, Johnson C, et al. Lumpectomy and radiation treatment for invasive lobular carcinoma of the breast. *Am J Surg* 1996;**172**:496–500.
14. Fisher ER, Fisher B. Lobular carcinoma of the breast: an overview. *Ann Surg* 1977;**185**:377–85.
15. Arpino G, Bardou VJ, Clark GM, Elledge RM. Infiltrating lobular carcinoma of the breast: tumor characteristics and clinical outcome. *Breast Cancer Res* 2004;**6**:R149–56.
16. Yeatman TJ, Cantor AB, Smith TJ, et al. Tumor biology of infiltrating lobular carcinoma. Implications for management. *Ann Surg* 1995;**222**: 549–59. discussion 559–561.
17. Poen JC, Tran L, Juillard G, et al. Conservation therapy for invasive lobular carcinoma of the breast. *Cancer* 1992;**69**:2789–95.
18. Weiss MC, Fowble BL, Solin LJ, et al. Outcome of conservative therapy for invasive breast cancer by histologic subtype. *Int J Radiat Oncol Biol Phys* 1992;**23**:941–7.
19. du Toit RS, Locker AP, Ellis IO, et al. Invasive lobular carcinomas of the breast – the prognosis of histopathological subtypes. *Br J Cancer* 1989;**60**:605–9.
20. Vo TN, Meric-Bernstam F, Yi M, et al. Outcomes of breast-conservation therapy for invasive lobular carcinoma are equivalent to those for invasive ductal carcinoma. *Am J Surg* 2006;**192**:552–5.
21. Regano S, Hernanz F, Ortega E, et al. Oncoplastic techniques extend breast-conserving surgery to patients with neoadjuvant chemotherapy response unfit for conventional techniques. *World J Surg* 2009;**33**:2082–6.
22. Hilleren DJ, Andersson IT, Lindholm K, Linnell FS. Invasive lobular carcinoma: mammographic findings in a 10-year experience. *Radiology* 1991;**178**:149–54.
23. Krecke KN, Gisvold JJ. Invasive lobular carcinoma of the breast: mammographic findings and extent of disease at diagnosis in 184 patients. *AJR Am J Roentgenol* 1993;**161**:957–60.
24. Dillon MF, Hill AD, Fleming FJ, et al. Identifying patients at risk of compromised margins following breast conservation for lobular carcinoma. *Am J Surg* 2006;**191**:201–5.
25. Morrow M, Jagsi R, Alderman AK, et al. Surgeon recommendations and receipt of mastectomy for treatment of breast cancer. *JAMA* 2009;**302**:1551–6.