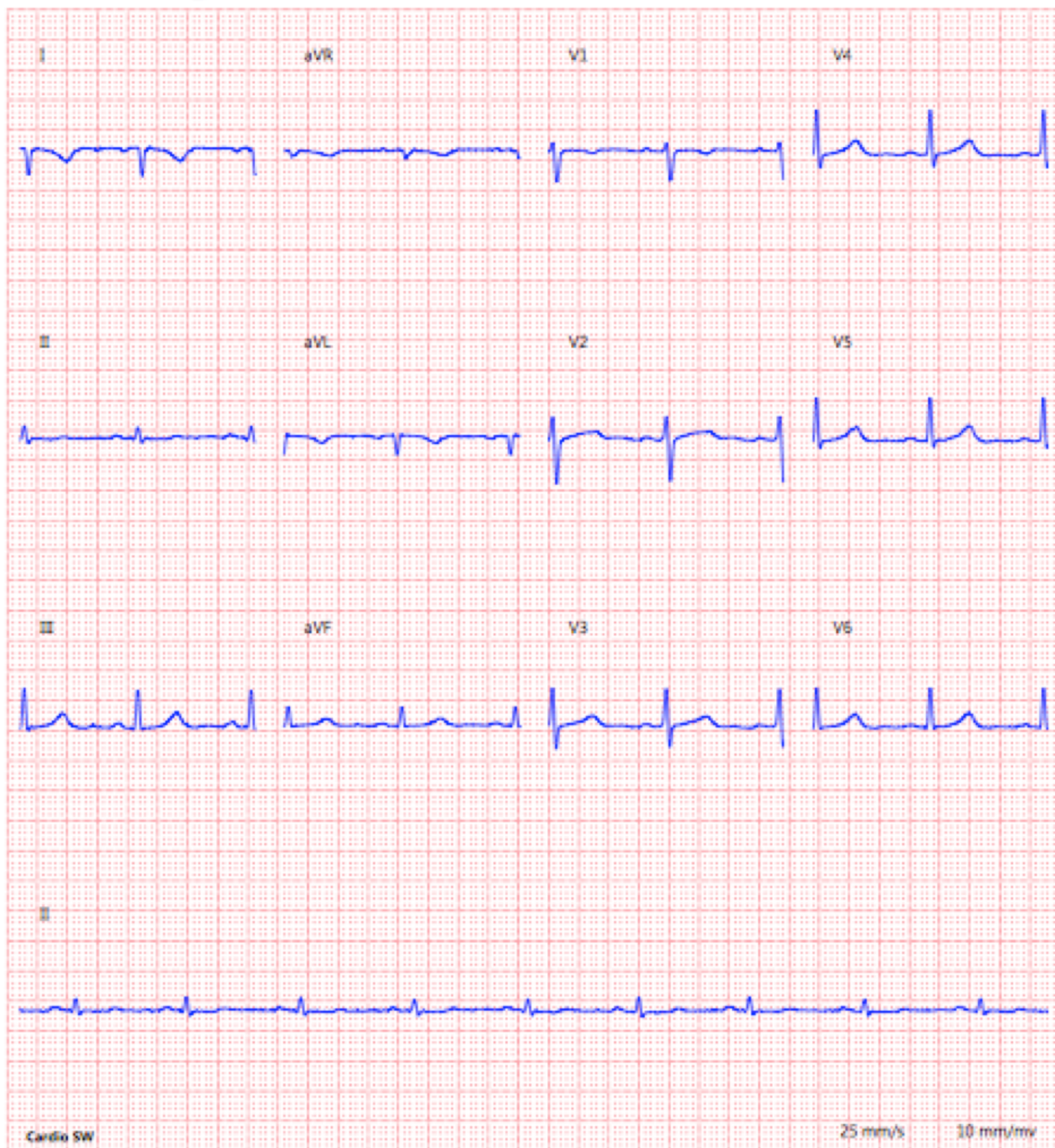


# Electrocardiograma

Paciente 9801980181P25 - Jose Rodriguez Hernandez



# Informe de ECG

Paciente 9801980181P25 - Jose Rodriguez Hernandez

## Ritmo Cardíaco

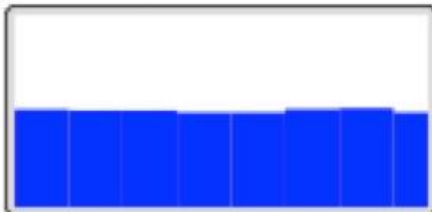
FC

0

ipm



## Intervalos R-R



## Intervalos

PR

-

seg

QRS

0.00

seg

QT

0.00

seg

QTc

0.00

seg

## Amplitudes

1 mm = 0.1 mV

Onda P

1.0 mm en III

Q / QS

en IaVL

R (V1)

1.0 mm

R (aVL)

0.0 mm

S(V1)+R(V5)

12.6 mm

S(V1)+R(V6)

12.0 mm

Max J

0.3 mm en V6

Min ST

-0.5 mm en I

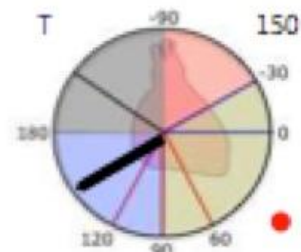
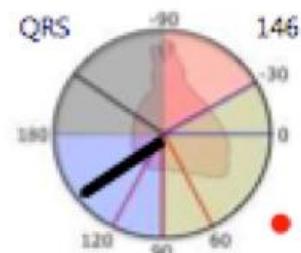
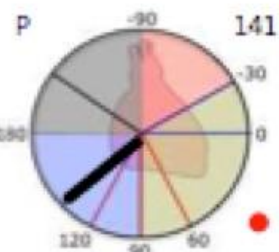
Max T

2.7 mm en III

T negativa

en IaVL, V1

## Ejes Eléctricos



Cardio SW

## Interpretación

Ritmo Sinusal Normal

Electrocardiograma dentro de límites normales

Dr. Carlos Manzano

CP 289808202  
ESPECIALISTA EN CARDIOLOGIA