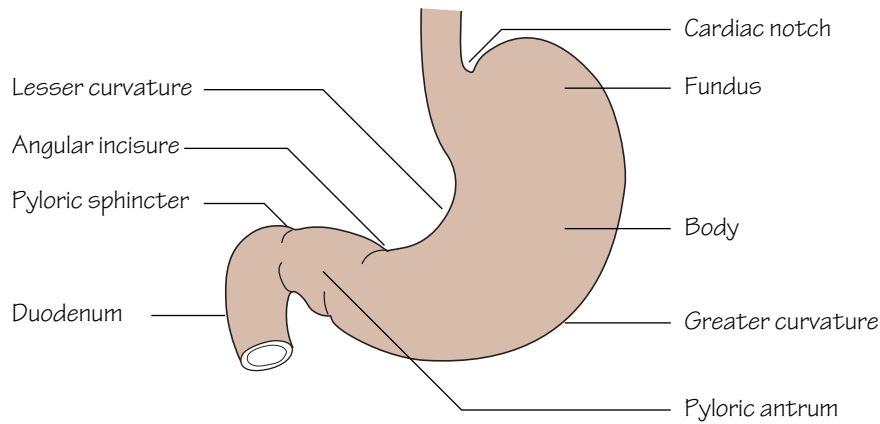
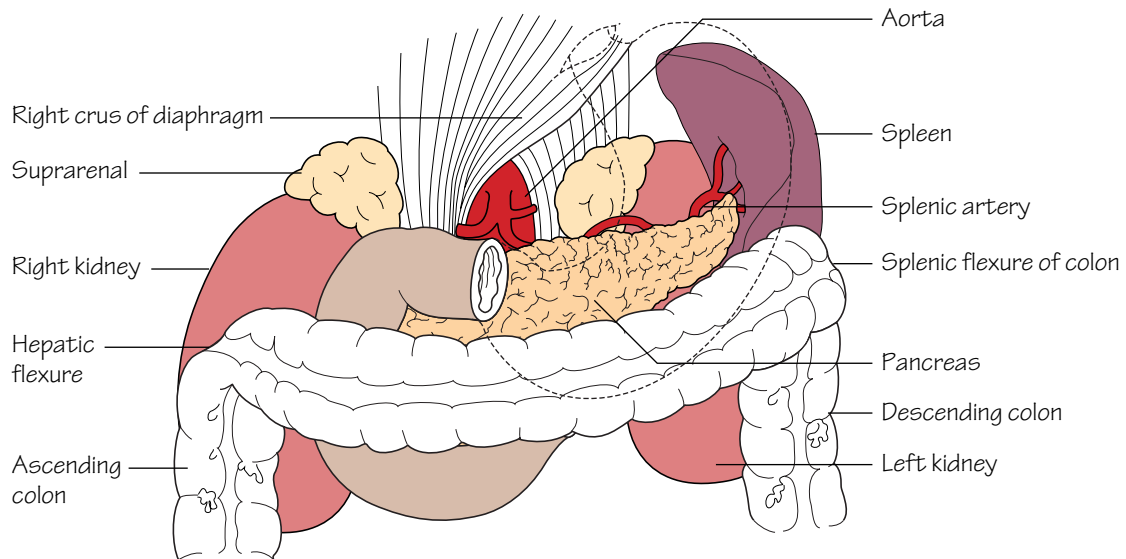


## 15 The upper gastrointestinal tract I



**Fig.15.1**

The subdivisions of the stomach



**Fig.15.2**

The stomach bed. For more detail see fig.19.1.

The stomach is outlined but the shape is by no means constant

The embryonic gut is divided into foregut, midgut and hindgut, supplied, respectively, by the coeliac, superior mesenteric and inferior mesenteric arteries. The foregut extends from the oesophagus to the entrance of the common bile duct into the second part of the duodenum. The midgut extends down to two-thirds of the way along the transverse colon. It largely develops outside the abdomen until this congenital 'umbilical hernia' is reduced during the 8th–10th week of gestation. The hindgut extends down to include the upper half of the anal canal.

### The abdominal oesophagus

- The abdominal oesophagus measures approximately 1 cm in length.
- It is accompanied by the anterior and posterior vagal trunks from the left and right vagi and the oesophageal branches of the left gastric artery.
- The lower third of the oesophagus is a site of porto-systemic venous anastomosis. This is formed between tributaries of the left gastric and azygos veins (p. 11).

### The stomach (Figs 15.1 and 15.2)

- The notch on the lesser curve, at the junction of the body and pyloric antrum, is the *incisura angularis*.
- The *pyloric sphincter* controls the release of stomach contents into the duodenum. The sphincter is composed of a thickened layer of circular smooth muscle which acts as an anatomical, as well as physiological, sphincter. The junction of the pylorus and duodenum can be seen externally as a constriction with an overlying vein—the *prepyloric vein* (of Mayo).
- The *cardiac orifice* represents the point of entry for oesophageal contents into the stomach. The cardiac sphincter acts to prevent reflux of stomach contents into the oesophagus. Unlike the pylorus there is no discrete anatomical sphincter at the cardia; however, multiple factors contribute towards its mechanism. These include: the arrangement of muscle fibres at the cardiac orifice acting as a physiological sphincter; the angle at which the oesophagus enters the stomach producing a valve effect; the right crus of the diaphragm surrounding the oesophagus and compression of the short segment of intra-abdominal oesophagus by increases in intra-abdominal pressure during straining, preventing reflux.
- The *lesser omentum* is attached to the lesser curvature and the *greater omentum* to the greater curvature. The omenta contain the blood and lymphatic supply to the stomach.
- The mucosa of the stomach is thrown into folds—*rugae*.
- **Blood supply** (see Fig. 12.2): the arterial supply to the stomach is exclusively from branches of the coeliac axis. Venous drainage is to the portal system (see Fig. 13.2).
- **Nerve supply**: the anterior and posterior vagal trunks arise from the oesophageal plexuses and enter the abdomen through the oesophageal hiatus. The *hepatic* branches of the anterior vagus pass to the liver. The *coeliac* branch of the posterior vagus passes to the coeliac ganglion from where it proceeds to supply the intestine down to the distal trans-

verse colon. The anterior and posterior vagal trunks descend along the lesser curve as the anterior and posterior nerves of *Latarjet* from which terminal branches arise to supply the stomach. The vagi provide a motor and secretory supply to the stomach. The latter includes a supply to the acid-secreting part—the *body*.

### The duodenum (Figs 19.1 and 19.2)

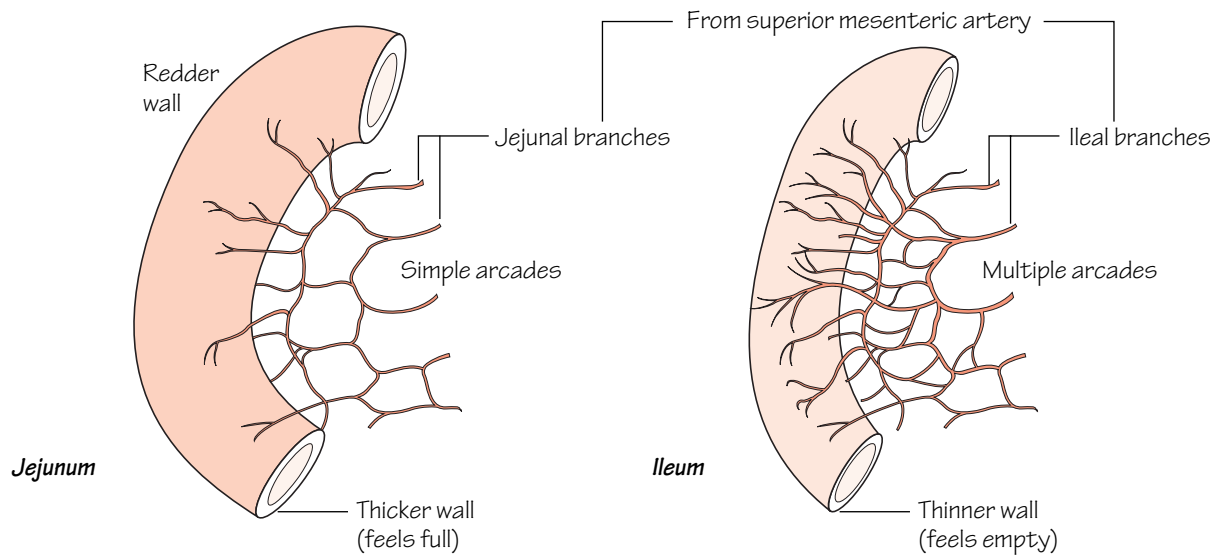
The duodenum is the first part of the small intestine. It is approximately 25 cm long and curves around the head of the pancreas. Its primary function is in the absorption of digested products. Despite its relatively short length the surface area is greatly enhanced by the mucosa being thrown into folds bearing villi which are visible only at a microscopic level. With the exception of the first 2.5 cm, which is completely covered by peritoneum, the duodenum is a retroperitoneal structure. It is considered in four parts:

- **First part** (5 cm).
- **Second part** (7.5 cm)—this part descends around the head of the pancreas. Internally, in the mid-section, a small eminence may be found on the posteromedial aspect of the mucosa—the *duodenal papilla*. This structure represents the site of the common opening of the bile duct and *main pancreatic duct* (of *Wirsung*). The *sphincter of Oddi* guards this common opening. A smaller *subsidiary pancreatic duct* (of *Santorini*) opens into the duodenum a small distance above the papilla.
- **Third part** (10 cm)—this part is crossed anteriorly by the root of the mesentery and superior mesenteric vessels.
- **Fourth part** (2.5 cm)—this part terminates as the duodenojejunal junction. The termination of the duodenum is demarcated by a peritoneal fold stretching from the junction to the right crus of the diaphragm covering the *suspensory ligament of Treitz*. The terminal part of the inferior mesenteric vein lies adjacent to the duodenojejunal junction and serves as a useful landmark.
- **Blood supply** (see Fig. 12.2): the superior and inferior pancreaticoduodenal arteries supply the duodenum and run between this structure and the pancreatic head. The superior artery arises from the coeliac axis and the inferior from the superior mesenteric artery.

### Peptic ulcer disease

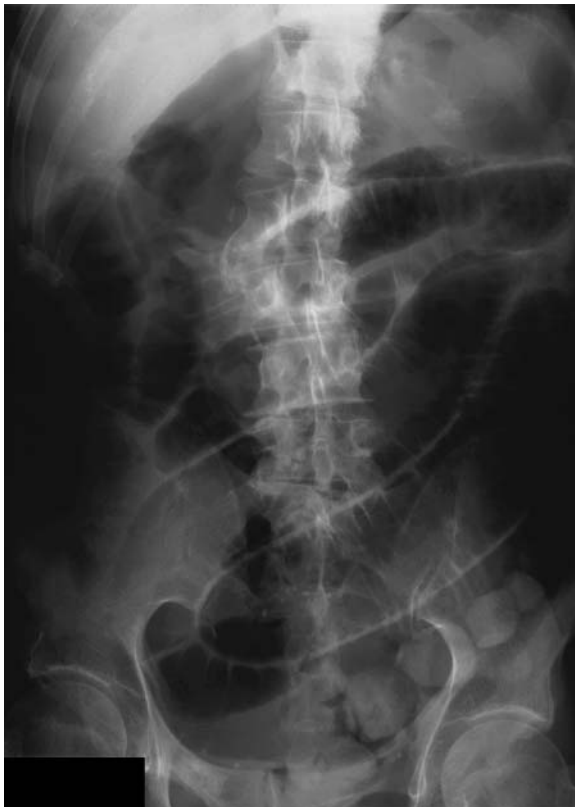*Most peptic ulcers occur in the stomach and proximal duodenum. They arise as a result of an imbalance between acid secretion and mucosal defences. Helicobacter pylori infection is a significant aetiological factor and the eradication of this organism, as well as the attenuation of acid secretion, form the cornerstones of medical treatment. In a minority of cases the symptoms are not controlled by medical treatment alone and surgery is required. 'Very highly selective vagotomy' is a technique where only the afferent vagal fibres to the acid-secreting body are denervated thus not compromising the motor supply to the stomach and hence bypassing the need for a drainage procedure (e.g. gastrojejunostomy).*

## 16 The upper gastrointestinal tract II



**Fig.16.1**

The jejunum and the ileum can be distinguished by their colour, feel and the complexity of the arterial arcades



**Fig.16.2**

Small bowel obstruction, showing dilated bowel loops

### **The small intestine** (Fig. 16.1)

The small intestine is approximately 6 m long and comprises the duodenum, jejunum and ileum. A large internal surface area throughout the small intestine facilitates absorption of digested products. The small intestine is suspended from the posterior abdominal wall by its mesentery which contains the superior mesenteric vessels, lymphatics and autonomic nerves. The origin of the mesentery measures approximately 15 cm and passes from the duodenojejunal flexure to the right sacro-iliac joint. The distal border is obviously the same length as the intestine. No sharp distinction occurs between the jejunum and ileum; however, certain characteristics help distinguish between them:

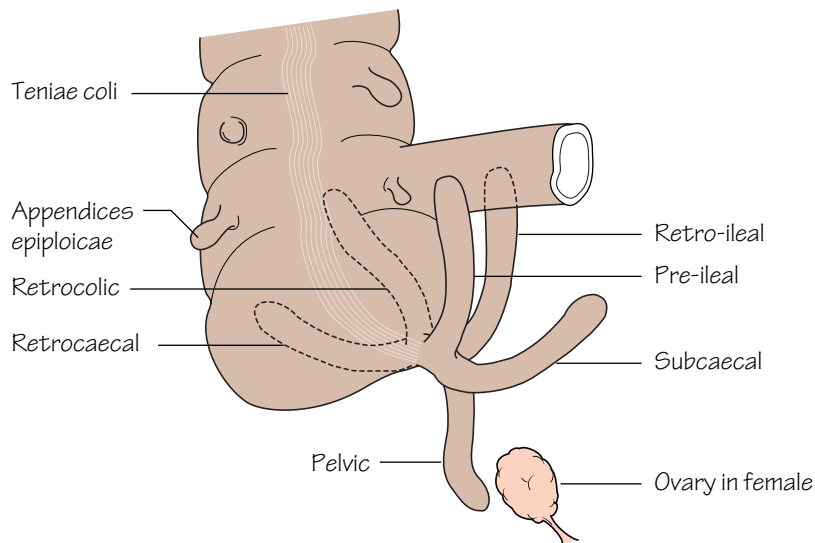
- Excluding the duodenum, the proximal two-fifths of the small intestine comprises jejunum whereas the remaining distal three-fifths comprises ileum. Loops of jejunum tend to occupy the umbilical region whereas the ileum occupies the lower abdomen and pelvis.
- The mucosa of the small intestine is thrown into circular folds—the *valvulae conniventes*. These are more prominent in the jejunum than in the ileum.
- The diameter of the jejunum tends to be greater than that of the ileum.
- The mesentery to the jejunum tends to be thicker than that for the ileum.

- The superior mesenteric vessels (see Fig. 12.3) pass over the third part of the duodenum to enter the root of the mesentery and pass towards the right iliac region on the posterior abdominal wall. Jejunal and ileal branches arise which divide and re-anastomose within the mesentery to produce arcades. End-artery vessels arise from the arcades to supply the gut wall. The arterial supply to the jejunum consists of few arcades and little terminal branching whereas the vessels to the ileum form numerous arcades and much terminal branching of end-arteries passing to the gut wall.

### **Small bowel obstruction** (Fig. 16.2)

*Small bowel obstruction (SBO) can occur due to luminal, mural or extraluminal factors that result in luminal blockage. Post surgical adhesions and herniae are the most frequent causes. Many cases resolve with conservative measures only; however, if any deterioration in the clinical picture occurs to suggest intestinal infarction or perforation an exploratory laparotomy is mandatory. The classical X-ray features of SBO are those of dilated small bowel loops. These can be distinguished from large bowel as the valvulae conniventes (present only in the small bowel) can be identified traversing the entire lumen whereas the small bowel haustra only partially traverse the lumen.*

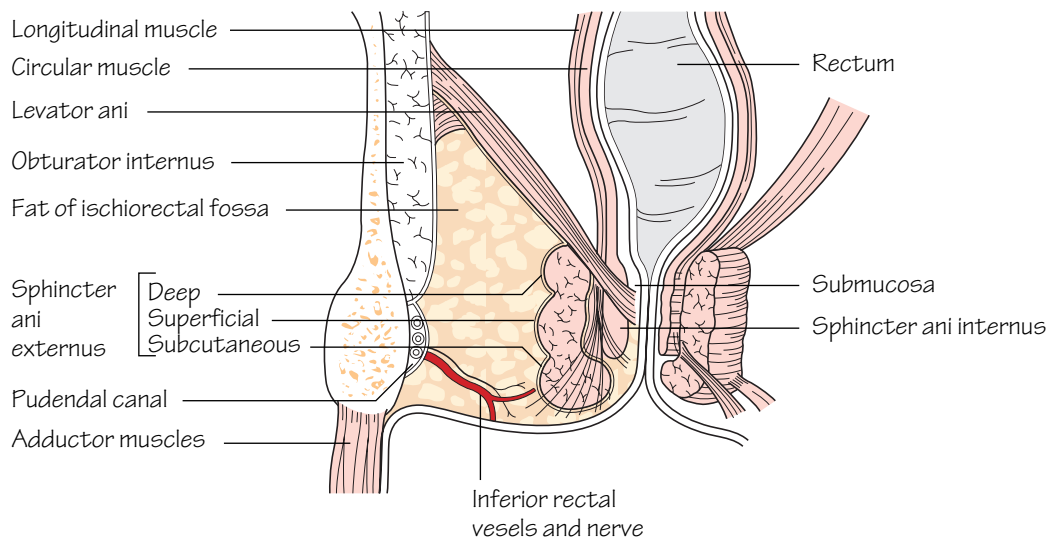
## 17 The lower gastrointestinal tract



**Fig.17.1**

The various positions in which the appendix may be found.

In the pelvic position the appendix may be close to the ovary in the female



**Fig.17.2**

A coronal section through the pelvis to show the anal sphincters and the ischioanal fossa

### The caecum and colon (Figs 17.1, 12.3, 12.5)

In adults, the large bowel measures approximately 1.5 m. The caecum, ascending, transverse, descending and sigmoid colon have similar characteristic features. These are that they possess:

- *Appendices epiploicae* (Fig. 17.1): these are fat-laden peritoneal tags present over the surface of the caecum and colon.
- *Teniae coli* (Fig. 17.1): these are three flattened bands representing the condensed longitudinal muscular coat of the large intestine. They course from the base of the appendix (and form a useful way of locating this structure at operation) to the recto-sigmoid junction.
- *Sacculations*: because the teniae are shorter than the bowel itself the colon takes on a sacculated appearance. These sacculations are visible not only at operation but also radiographically. On a plain abdominal X-ray, the colon, which appears radiotranslucent because of the gas within, has shelf-like processes (*haustra*) which partially project into the lumen.

The transverse and sigmoid colon are each attached to the posterior abdominal wall by their respective mesocolons and are covered entirely by peritoneum. Conversely, the ascending and descending colon normally possess no mesocolon. They are adherent to the posterior abdominal wall and covered only anteriorly by peritoneum.

### The appendix (Fig. 17.1)

The appendix varies enormously in length but in adults it is approximately 5–15 cm long. The base of the appendix arises from the postero-medial aspect of the caecum; however, the lie of the appendix itself is highly variable. In most cases the appendix lies in the retrocaecal position but other positions frequently occur. The appendix has the following characteristic features:

- It has a small mesentery which descends behind the terminal ileum. The only blood supply to the appendix, the appendicular artery (a branch of the ileocolic), courses within its mesentery (see Fig. 12.4). *In cases of appendicitis the appendicular artery ultimately thromboses. When this occurs, gangrene and perforation of the appendix inevitably supervene.*
- The appendix has a lumen which is relatively wide in infants and gradually narrows throughout life, often becoming obliterated in the elderly.
- The teniae coli of the caecum lead to the base of the appendix.
- The *bloodless fold of Treves* (ileocaecal fold) is the name given to a small peritoneal reflection passing from the anterior terminal ileum to the appendix. Despite its name it is not an avascular structure!

*Appendectomy is performed most commonly through a grid-iron muscle-splitting incision. The appendix is first located and then delivered into the wound. The mesentery of the appendix is then divided and ligated. The appendix is then tied at its base, excised and removed. Most surgeons still opt to invaginate the appendix stump as a precautionary measure against slippage of the stump ligature.*

### The rectum (Figs 17.2, 12.5)

- The rectum measures 10–15 cm in length. It commences in front of the 3rd sacral vertebra as a continuation of the sigmoid colon and follows the curve of the sacrum anteriorly. It turns backwards abruptly in front of the coccyx to become the anal canal.
- The mucosa of the rectum is thrown into three horizontal folds that project into the lumen—the *valves of Houston*.
- The rectum lacks haustrations. The teniae coli fan out over the rectum to form anterior and posterior bands.
- The rectum is slightly dilated at its lower end—the *ampulla*, and is supported laterally by the levator ani.
- Peritoneum covers the upper two-thirds of the rectum anteriorly but only the upper third laterally. In the female it is reflected forwards onto the uterus forming the *recto-uterine pouch* (*pouch of Douglas*). The rectum is separated from anterior structures by a tough fascial sheet—the *rectovesical* (*Denonvilliers*) *fascia*.

### The anal canal (Fig. 17.2)

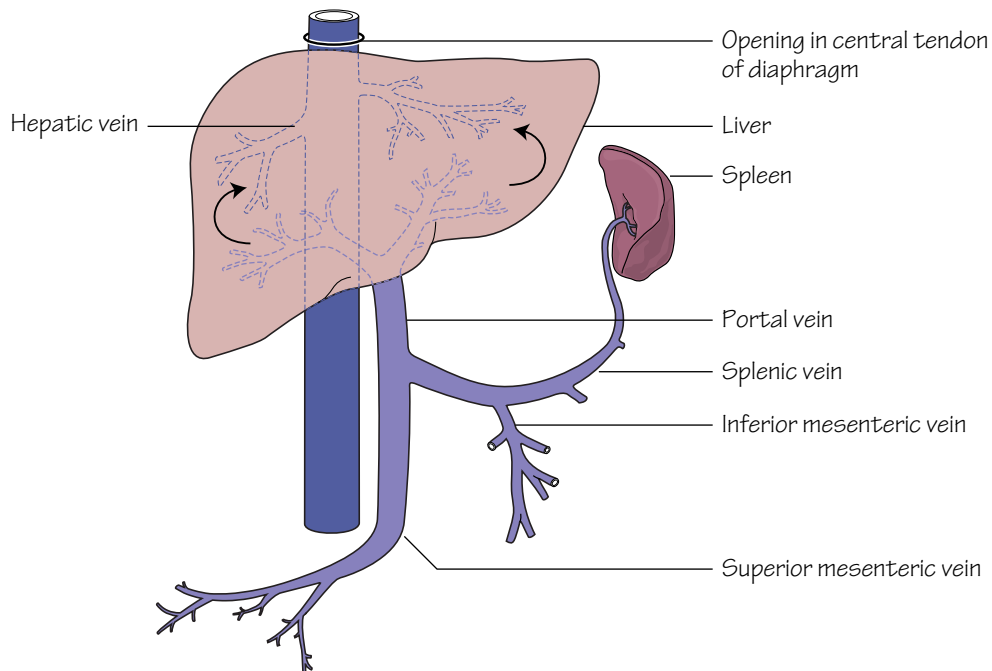
The anorectal junction is slung by the puborectalis component of levator ani which pulls it forwards. The canal is approximately 4 cm long and angled postero-inferiorly. Developmentally the midpoint of the anal canal is represented by the *dentate line*. This is the site where the proctodeum (ectoderm) meets endoderm. This developmental implication is reflected by the following characteristics of the anal canal:

- The epithelium of the upper half of the anal canal is columnar. In contrast the epithelium of the lower half of the anal canal is squamous. The mucosa of the upper canal is thrown into vertical columns (*of Morgagni*). At the bases of the columns are valve-like folds (*valves of Ball*). The level of the valves is termed the dentate line.
- The blood supply to the upper anal canal (see Fig. 12.5) is from the superior rectal artery (derived from the inferior mesenteric artery) whereas the lower anal canal is supplied by the inferior rectal artery (derived from the internal iliac artery). As mentioned previously, the venous drainage follows suit and represents a site of porto-systemic anastomosis (see p. 35).
- The upper anal canal is insensitive to pain as it is supplied by autonomic nerves only. The lower anal canal is sensitive to pain as it is supplied by somatic innervation (inferior rectal nerve).
- The lymphatics from the upper canal drain upwards along the superior rectal vessels to the internal iliac nodes whereas lymph from the lower anal canal drains to the inguinal nodes.

### The anal sphincter

See Chapter 25.

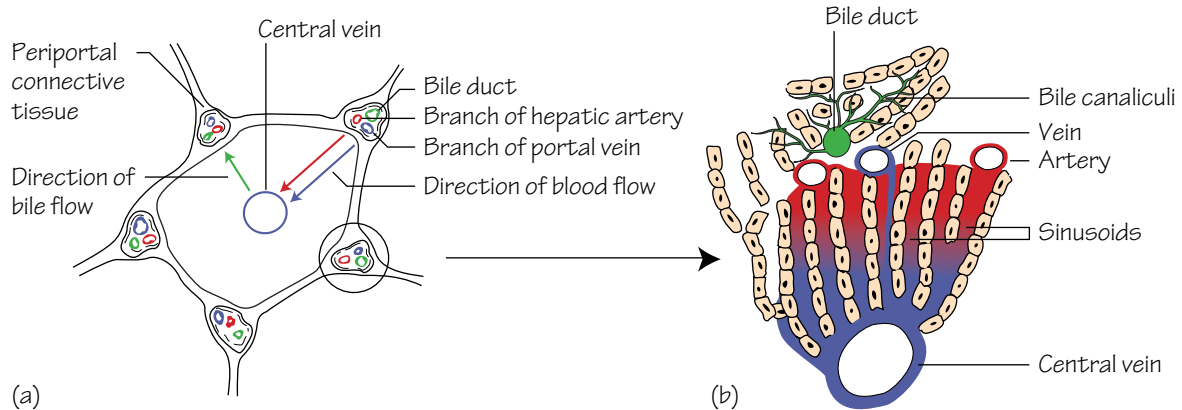
## 18 The liver, gall-bladder and biliary tree



**Fig.18.1**

The venous circulation through the liver.

The transmission of blood from the portal system to the inferior vena cava is via the liver lobules (fig. 18.2)



**Fig.18.2**

(a) A liver lobule to show the direction of blood flow from the portal system to the centrilobular veins and thence to the inferior vena cava

(b) The blood flow through the sinusoids of the liver lobule and the passage of bile from the bile canaliculi to the bile ducts

## The liver (see Fig. 14.3)

- The liver predominantly occupies the right hypochondrium but the left lobe extends to the epigastrium. Its domed upper (*diaphragmatic*) surface is related to the diaphragm and its lower border follows the contour of the right costal margin. *When the liver is enlarged the lower border becomes palpable below the costal margin.*
- The liver anatomically consists of a large right lobe, and a smaller left lobe. These are separated antero-superiorly by the falciform ligament and postero-inferiorly by *fissures for the ligamentum venosum and ligamentum teres*. In the anatomical classification the right lobe includes the caudate and quadrate lobes. Functionally, however, the caudate and most of the quadrate lobes are units of the left lobe as they receive their blood supplies from the left hepatic artery and deliver their bile into the left hepatic duct. Hence, the functional classification of the liver defines the right and left lobes as separated by a vertical plane extending posteriorly from the gall-bladder to the inferior vena cava (IVC).
- When the postero-inferior (*visceral*) surface of the liver is seen from behind an H-shaped arrangement of grooves and fossae is identified. The boundaries of the H are formed as follows:
  - *Right anterior limb*—the gall-bladder fossa.
  - *Right posterior limb*—the groove for the IVC.
  - *Left anterior limb*—the fissure containing the ligamentum teres (the fetal remnant of the left umbilical vein which returns oxygenated blood from the placenta to the fetus).
  - *Left posterior limb*—the fissure for the ligamentum venosum (the latter structure is the fetal remnant of the ductus venosus; in the fetus the ductus venosus serves to partially bypass the liver by transporting blood from the left umbilical vein to the IVC).
  - *Horizontal limb*—the *porta hepatis*. The caudate and quadrate lobes of the liver are the areas defined above and below the horizontal bar of the H, respectively.
- The *porta hepatis* is the hilum of the liver. It transmits (from posterior to anterior) the: portal vein (Fig. 18.1); branches of the hepatic artery and hepatic ducts. The porta is enclosed within a double layer of peritoneum—the lesser omentum, which is firmly attached to the ligamentum venosum in its fissure.
- The liver is covered by peritoneum with the exception of the ‘bare area’.
- The liver is made up of multiple functional units—*lobules* (Fig. 18.2). Branches of the portal vein and hepatic artery transport blood through portal canals into a central vein by way of sinusoids which traverse the lobules. The central veins ultimately coalesce into the right, left and central hepatic veins which drain blood from corresponding liver areas backwards into the IVC. The portal canals also contain tributaries of the

hepatic ducts which serve to drain bile from the lobule down the biliary tree from where it can be concentrated in the gall-bladder and eventually released into the duodenum. *The extensive length of gut that is drained by the portal vein explains the predisposition for intestinal tumours to metastasize to the liver.*

## The gall-bladder (see Fig. 14.3)

The gall-bladder lies adherent to the undersurface of the liver in the transpyloric plane (p. 53) at the junction of the right and quadrate lobes. The duodenum and the transverse colon are behind it.

The gall-bladder acts as a reservoir for bile which it concentrates. It usually contains approximately 50 mL of bile which is released through the cystic and then common bile ducts into the duodenum in response to gall-bladder contraction induced by gut hormones.

- **Structure:** the gall-bladder comprises a *fundus*, a *body* and a *neck* (which opens into the cystic duct).
- **Blood supply:** the arterial supply to the gall-bladder is derived from two sources: the cystic artery which is usually, but not always, a branch of the right hepatic artery, and small branches of the hepatic arteries which pass via the fossa in which the gall-bladder lies. The cystic artery represents the most significant source of arterial supply. There is, however, no corresponding cystic vein but venous drainage occurs via small veins passing through the gall-bladder bed.

## The biliary tree

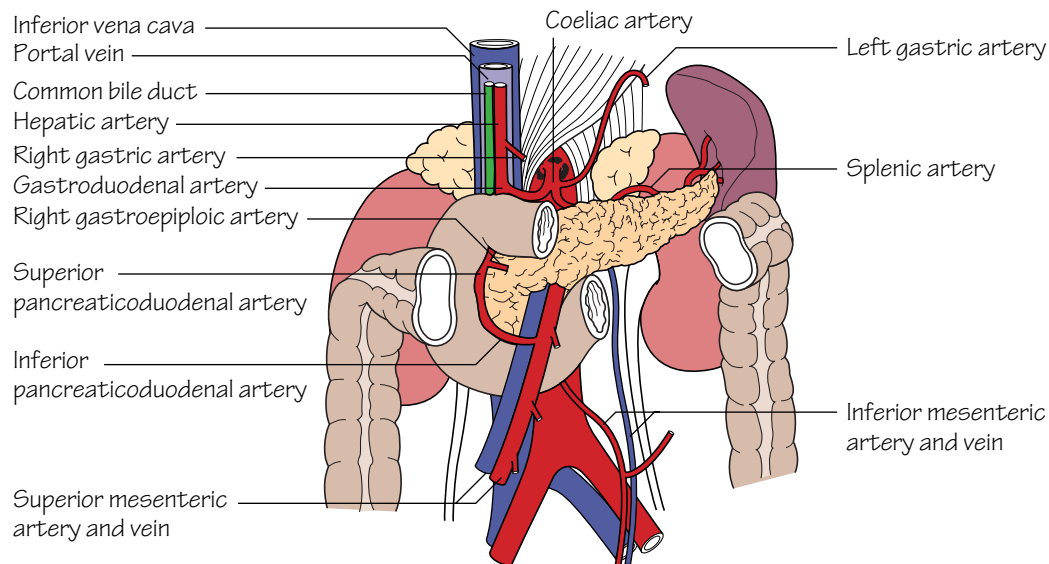
The common hepatic duct is formed by the confluence of the right and left hepatic ducts in the porta hepatis. The common hepatic duct is joined by the cystic duct to form the common bile duct. This structure courses, sequentially, in the free edge of the lesser omentum, behind the first part of the duodenum and in the groove between the second part of the duodenum and the head of the pancreas. It ultimately opens at the papilla on the medial aspect of the second part of the duodenum.

The common bile duct usually, but not always, joins with the main *pancreatic duct* (*of Wirsung*) (p. 47).

## Cholelithiasis

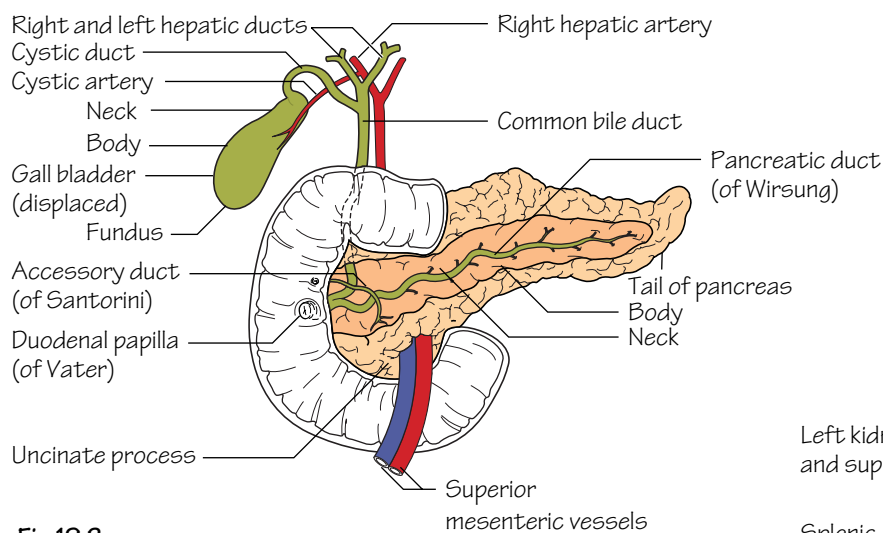
*Gallstones are composed of either cholesterol, bile pigment, or, more commonly, a mixture of these two constituents. Cholesterol stones form due to an altered composition of bile resulting in the precipitation of cholesterol crystals. Most gallstones are asymptomatic; however, when they migrate down the biliary tree they can be responsible for a diverse array of complications such as: acute cholecystitis, biliary colic, cholangitis and pancreatitis.*

## 19 The pancreas and spleen



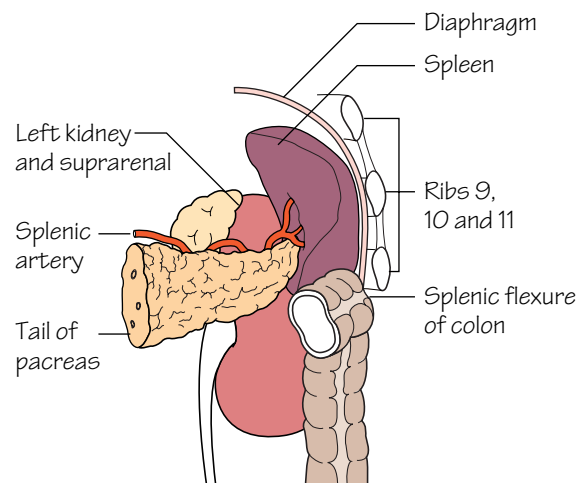
**Fig.19.1**

The relations of the pancreas



**Fig.19.2**

The ducts of the pancreas and the biliary system



**Fig.19.3**

The relations of the spleen

## The pancreas (Figs 19.1 and 19.2)

The pancreas has a: *head, neck, body* and *tail*. It is a retroperitoneal organ which lies roughly along the transpyloric plane. The head is bound laterally by the curved duodenum and the tail extends to the hilum of the spleen in the lienorenal ligament. The superior mesenteric vessels pass behind the pancreas, then anteriorly, over the *uncinate process* and third part of the duodenum into the root of the small bowel mesentery. The inferior vena cava, aorta, coeliac plexus, left kidney (and its vessels) and the left adrenal gland are posterior pancreatic relations. In addition, the portal vein is formed behind the pancreatic neck by the confluence of the splenic and superior mesenteric veins. The lesser sac and stomach are anterior pancreatic relations.

- **Structure:** the main *pancreatic duct (of Wirsung)* courses the length of the gland, ultimately draining pancreatic secretions into the *ampulla of Vater*, together with the common bile duct, and thence into the second part of the duodenum. An *accessory duct (of Santorini)* drains the uncinate process of the pancreas, opening slightly proximal to the ampulla into the second part of the duodenum.

- **Blood supply:** the pancreatic head receives its supply from the superior and inferior pancreaticoduodenal arteries. The splenic artery courses along the upper border of the body of the pancreas which it supplies by means of a large branch—the *arteria pancreatica magna*—and numerous smaller branches.

- **Function:** the pancreas is a lobulated structure which performs both exocrine and endocrine functions. The exocrine secretory glands drain pancreatic juice into the pancreatic ducts and, from there, ultimately into the duodenum. The secretion is essential for the digestion and absorption of proteins, fats and carbohydrates. The endocrine pancreas is responsible for the production and secretion of glucagon and insulin, which take place in specialized cells of the islets of Langerhans.

## Acute pancreatitis

*The presence of gallstones and a history of excessive alcohol intake are the predominant associations for pancreatitis. The mechanism by which these aetiological factors result in pancreatic injury is unknown; however, they both appear to result in activation of pancreatic exocrine pro-enzymes with resultant autodigestion. Even today, the mortality rate for severe acute pancreatitis remains in the region of 20%.*

## The spleen (Fig. 19.3)

The spleen is approximately the size of a clenched fist and lies directly below the left hemidiaphragm which, in addition to the pleura, separates it from the overlying 9th, 10th and 11th ribs.

- **Peritoneal attachments:** the splenic capsule is fibrous with peritoneum adherent to its surface. The gastrosplenic and lienorenal ligaments attach it to the stomach and kidney, respectively. The former ligament carries the short gastric and left gastroepiploic vessels to the fundus and greater curvature of the stomach, and the latter ligament carries the splenic vessels and tail of the pancreas towards the left kidney.

- **Blood supply:** is from the splenic artery to the hilum of the spleen. Venous drainage is to the splenic vein, thence to the portal vein.

- **Structure:** the spleen is a highly vascular reticulo-endothelial organ. It consists of a thin capsule from which trabeculae extend into the splenic pulp. In the spleen, the immunological centres, i.e. the lymphoid follicles (the *white pulp*), are scattered throughout richly vascularized sinusoids (the *red pulp*).

## Splenectomy

*As the spleen is a highly vascular organ, any injury to it can be life-threatening. Under these circumstances splenectomy must be carried out urgently. The technique used differs slightly when the procedure is performed for emergency as opposed to elective indications, but the principles are similar. Splenectomy involves: ligature of the splenic vessels approaching the hilum (taking care not to injure the tail of the pancreas or colon); and dissection of the splenic pedicles—the gastro-splenic (including the short gastric vessels) and lienorenal ligaments. As the spleen is an important immunological organ, postsplenectomy patients are rendered immunocompromised to capsulated bacteria. The latter organisms (e.g. meningococcus, pneumococcus) require opsonization for elimination and splenic lymphoid follicles are the principal sites where this takes place. Hence, following splenectomy, all patients are routinely vaccinated against the capsulated bacteria, and children, who are the group most at risk of sepsis, are maintained on long-term antibiotic prophylaxis.*