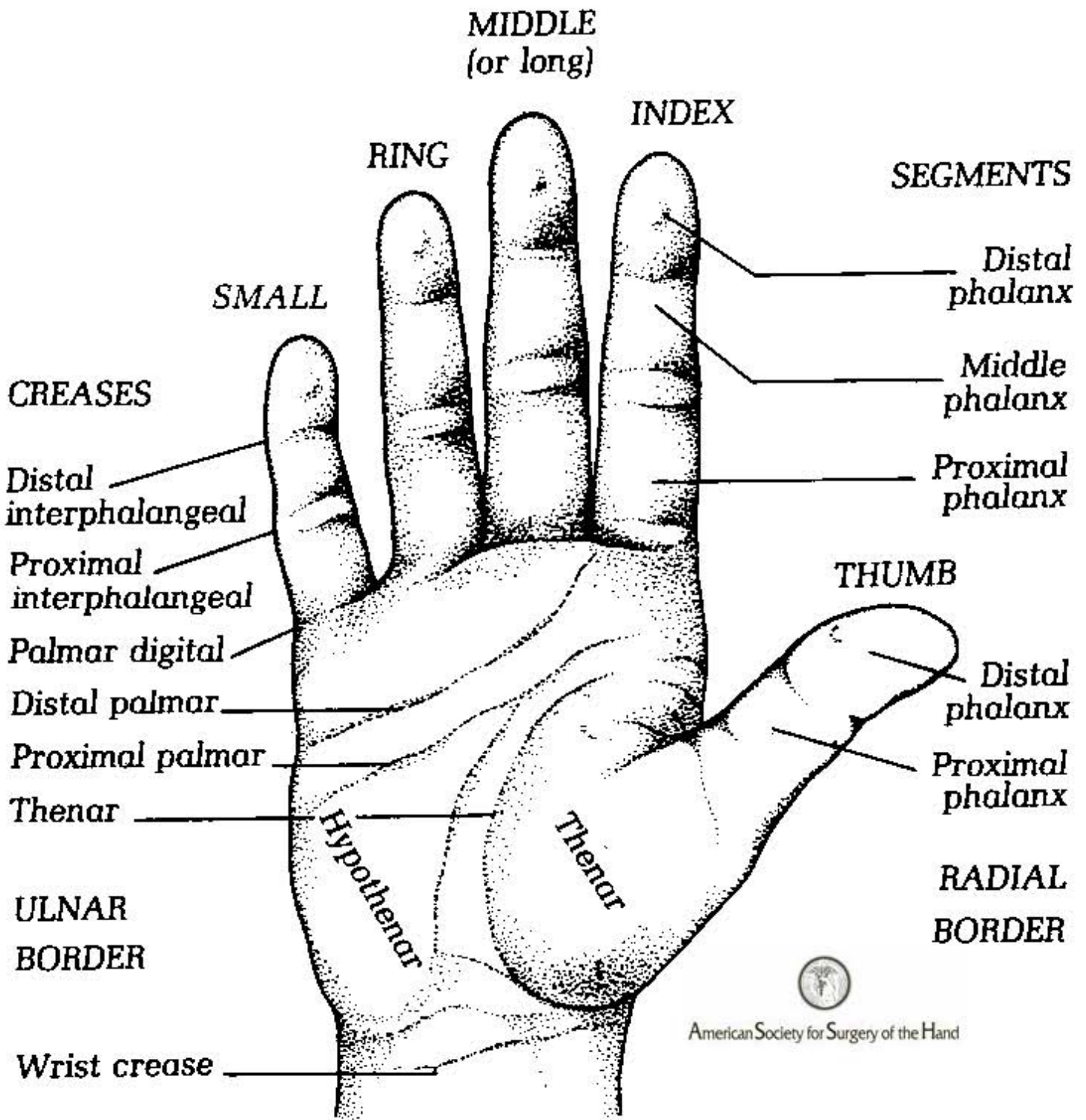


SURFACE ANATOMY
(Palmar surface)



JOINTS

Distal interphalangeal (DIP)

Proximal interphalangeal (PIP)

Metacarpophalangeal (MCP)

BONES

Interphalangeal

Metacarpophalangeal

Carpometacarpal (basilar joint)

Distal phalanges

Middle phalanges

Proximal phalanges

Metacarpals

Hamate

Pisiform

Triquetrum

Capitate

Lunate

Trapezoid

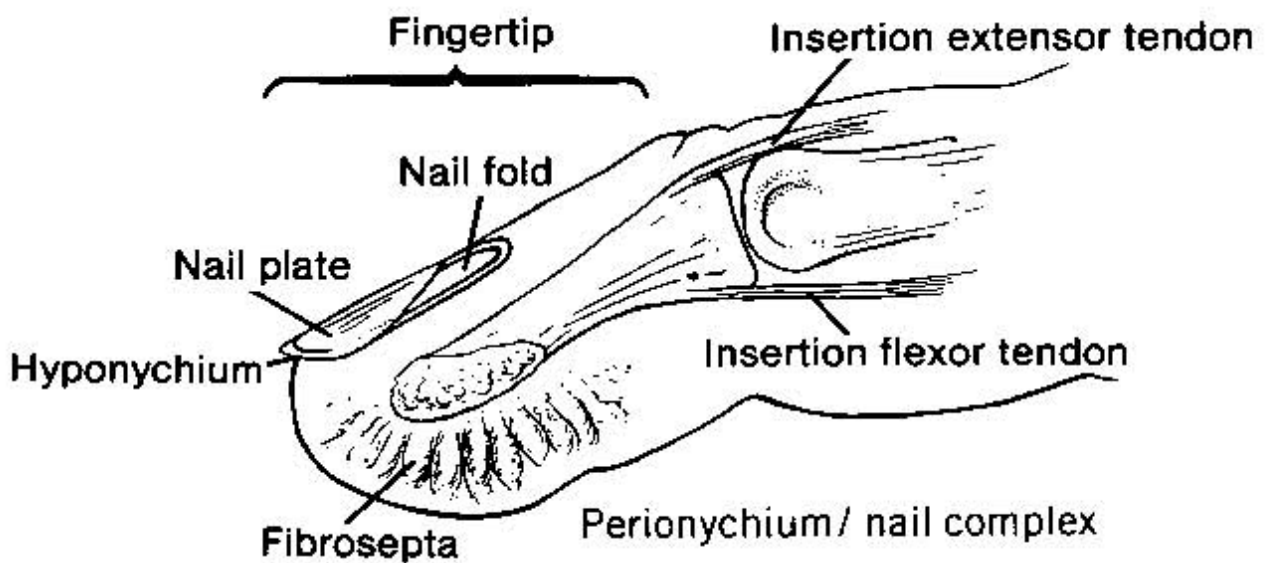
Trapezium

Scaphoid

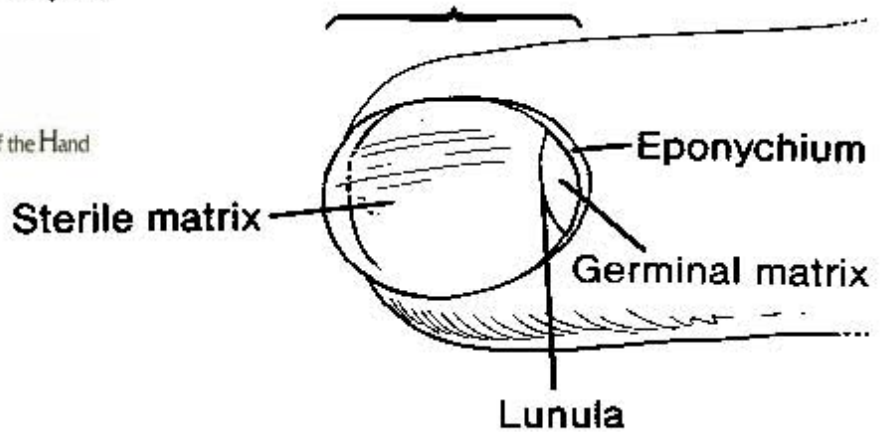


American Society for Surgery of the Hand

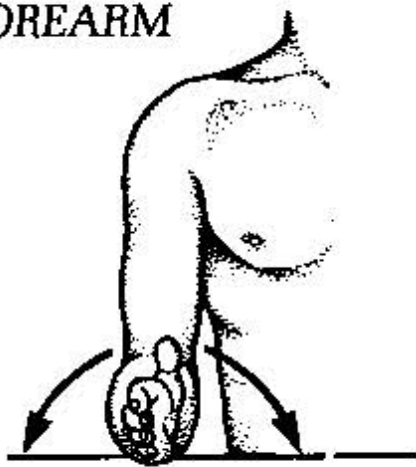
FINGERTIP AND NAIL COMPLEX



American Society for Surgery of the Hand



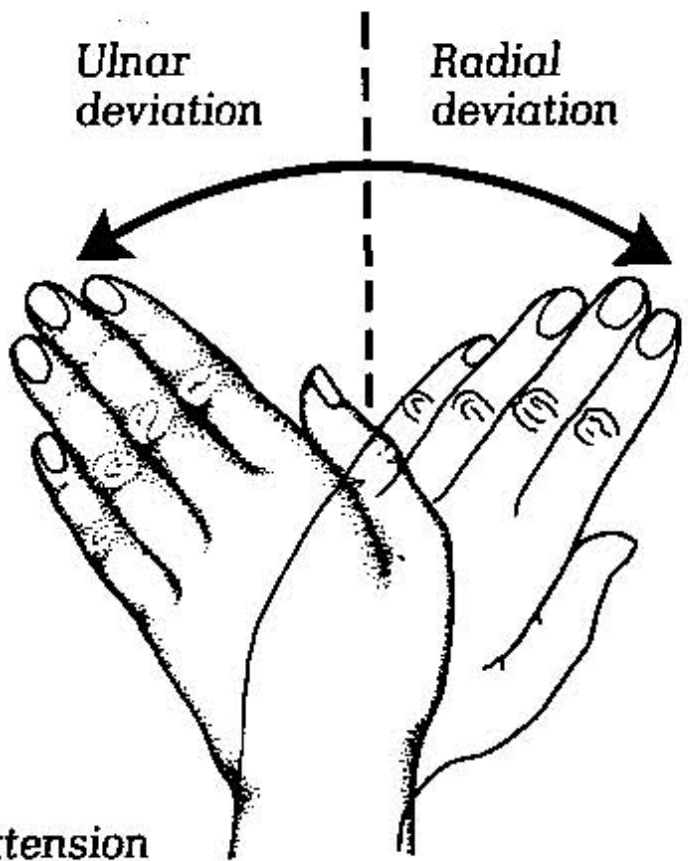
FOREARM



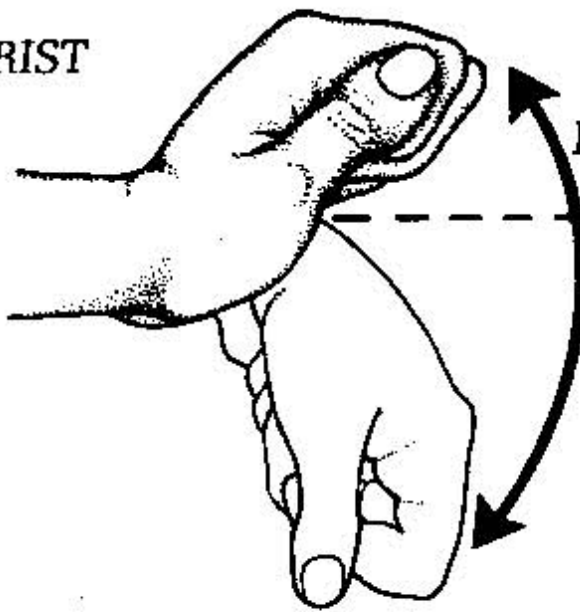
Supination Pronation

Ulnar deviation

Radial deviation



WRIST



Extension

Flexion

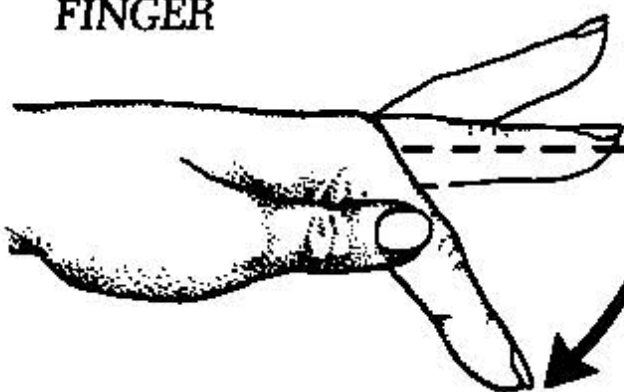


American Society for Surgery of the Hand

Abduction

Adduction

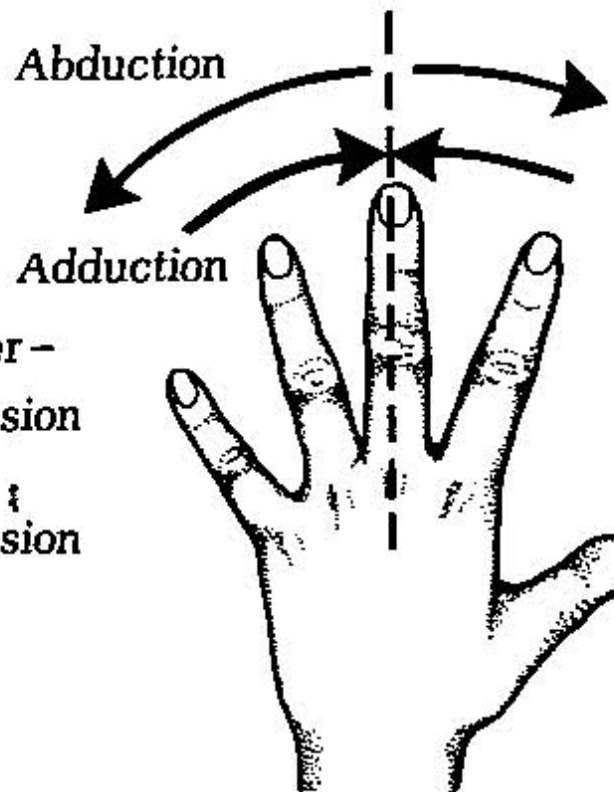
FINGER

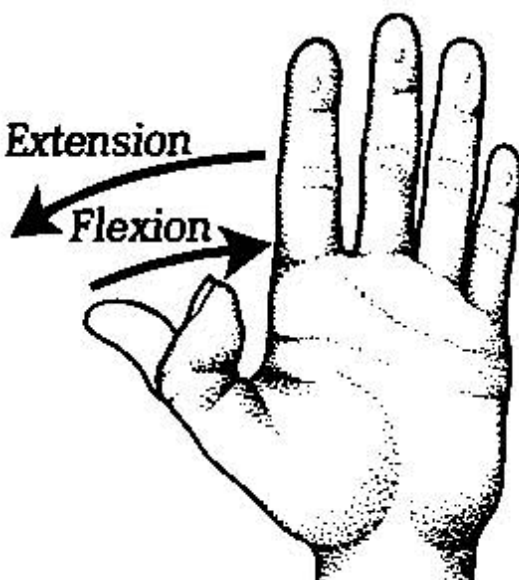


Hyper-extension

Extension

Flexion



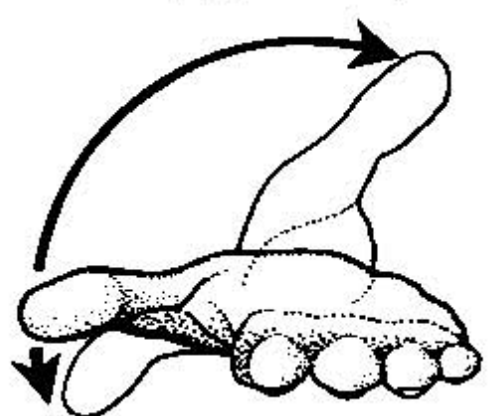
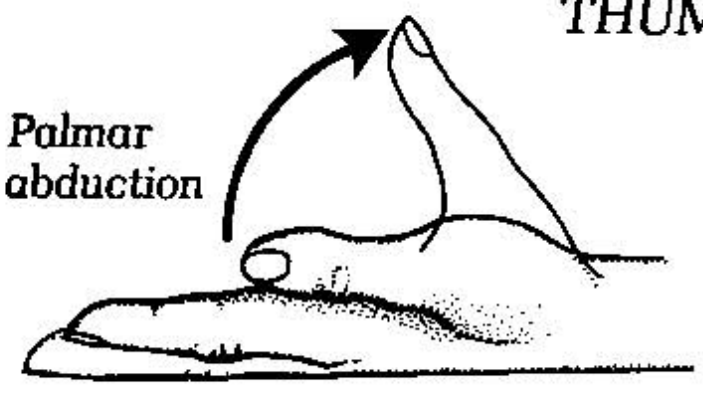


Opposing thumb to finger

Anteposition (opposition)

THUMB

Palmar abduction



Retroposition



American Society for Surgery of the Hand

Radial abduction

