



Masticatory Muscle Myositis: Pathogenesis, Diagnosis, and Treatment

Caeley Melmed, DVM, DACVIM*

Texas A&M University

G. Diane Shelton, DVM, PhD, DACVIM

University of California, San Diego

Robert Bergman, DVM, DACVIM

Claudia Barton, DVM, DACVIM

Texas A&M University

ABSTRACT:

Masticatory muscle myositis is an inflammatory myopathy in which patients most commonly present with jaw pain or inability to open the jaw. This disease is an autoimmune process in which circulating antibodies specifically target the masticatory muscles. Patients can present either in the acute or, more commonly, chronic phase of the disease. Dogs generally demonstrate no other neurologic or physical abnormalities, which may help differentiate this disease from other causes of trismus. Masticatory muscle myositis requires early detection and aggressive immunosuppressive therapy to improve the prognosis.

Masticatory muscle myositis is an autoimmune, focal inflammatory myopathy with clinical signs restricted to the muscles of mastication (Figure 1), including the temporalis, masseter, pterygoid, and rostral digastricus, all of which are innervated by the mandibular branch of the trigeminal nerve.^{1,2} The limb muscles are typically spared. Autoantibodies against masticatory muscle type 2M fibers are associated with masticatory muscle myositis and are useful in the diagnosis.³⁻⁵ This disease has historically been called *eosinophilic myositis* or *atrophic myositis*. Although these

names suggest a different pathogenesis, they likely rep-

resent the acute and chronic phases of masticatory muscle myositis.⁵ The acute phase is characterized clinically by jaw pain, trismus (i.e., inability to open the jaw), and swelling, and the chronic phase is characterized by marked muscle atrophy. Without early recognition and aggressive treatment, myofiber loss and muscle fibrosis may result in irreversible jaw dysfunction and severe muscle atrophy.

Although masticatory muscle myositis was once believed to be a form of polymyositis, further investigation has demonstrated that the disease represents a very unique myopathy. Initial studies comparing limb and masticatory muscle fibers demonstrated a significant difference in their fiber types.¹ Although limb and masticatory muscles are both composed of type 1 and 2 fibers, limb muscle contains type 1A

*Dr. Melmed is now affiliated with The Animal Diagnostic Clinic in Dallas, Texas.

Email comments/questions to
compendium@medimedia.com,
fax 800-556-3288, or log on to
www.VetLearn.com

Differential Diagnosis for Inflammatory Myopathy (Myositis)

Generalized

Infectious

Leptospirosis
Toxoplasmosis
Neosporosis
Leishmaniasis¹²
Hepatozoonosis
Rickettsia spp infection¹³
Dirofilaria immitis infection¹⁴
Clostridia spp infection¹⁵

Immune mediated

Systemic lupus erythematosus
Other connective tissue diseases
Drugs/toxins (e.g., cimetidine, trimethoprim-sulfadiazine, penicillamines)

Paraneoplastic/metastatic neoplasia

Thymoma
Lymphoma
Idiopathic disease

Focal

Masticatory muscle myositis
Extraocular muscle myositis

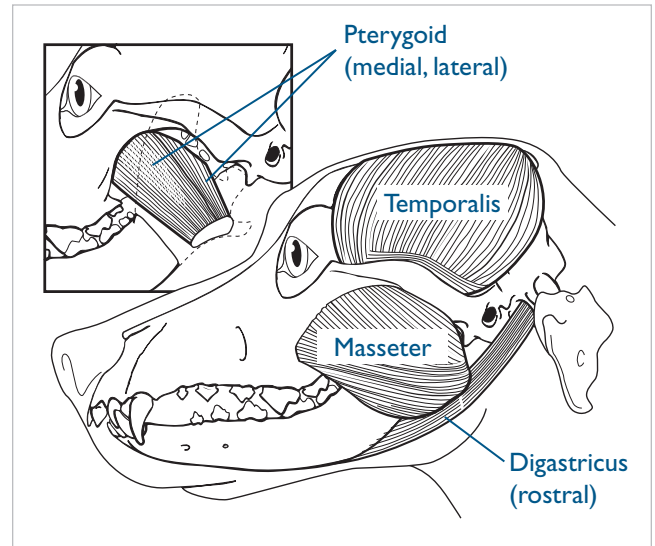


Figure 1. The muscles of mastication. (Illustration by Felicia Paras)

(i.e., slow twitch) and 2A (i.e., fast twitch) fibers, whereas masticatory muscle is composed of type 2M fibers and a type 1 fiber variant. Biochemical studies evaluating myosin isoforms by electrophoretic procedures demonstrated differences between limb muscle, fetal muscle, and masticatory muscle myosins.^{6,7} This

vating disorders. This supports the hypothesis that masticatory muscle myositis represents a targeted autoimmune process. Immunocytochemical staining using staphylococcal protein-A horseradish peroxidase conjugates have confirmed the presence of circulating and fixed antibodies (i.e., IgG) in approximately 85% of dogs with masticatory muscle myositis.⁴

It remains unknown what initiates formation of autoantibodies or why they are directed specifically against type 2M fibers. Some theories suggest that molecular mimicry may play a role, with antibodies or T cells generated in response to an infectious agent that subse-

The serum 2M antibody test is both highly sensitive (85% to 90%) and specific (100%) and is a preferred diagnostic test for masticatory muscle myositis.

unique type 2M myofiber isoform is likely related to the different motor nerve branches that develop during embryologic development.⁷

Researchers using immunocytochemical procedures documented autoantibodies against type 2M fibers in dogs with masticatory muscle myositis.^{3,4} More important, these antibodies were not reactive with any other muscle groups or found in any other muscle diseases, such as polymyositis, other polymyopathies, or dener-

quently cross-reacts with self-antigens. In this scenario, bacterial antigens would have a similar peptide sequence or conformational structure to some component of the 2M myofibers. Antibodies directed against these bacterial antigens could potentially cross-react with these myofibers.² There is precedent for this in the human literature because autoantibodies directed at *Streptococcus pyogenes* have been documented to attack cardiac and skeletal muscle.⁸ Other human diseases, such as peri-



Figure 2. Acute phase of masticatory muscle myositis.

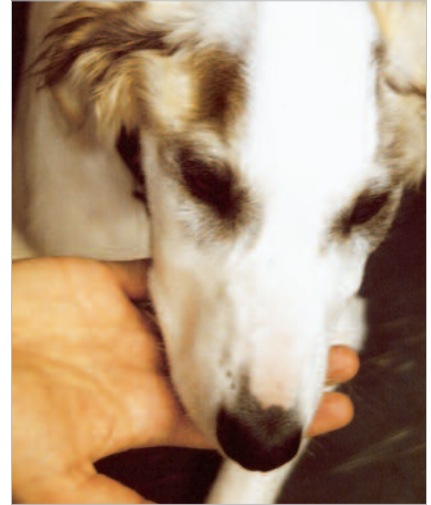

Figure 3. Muscle atrophy in a patient with masticatory muscle myositis.

carditis and rheumatoid arthritis, have been characterized by autoantibodies directed at specific myofibers.¹

DIAGNOSIS

The classical clinical presentation for masticatory muscle myositis is inability to open the jaw (trismus), jaw pain, and swelling or atrophy of the muscles of mastication. The average age of onset for masticatory muscle myositis is 3 years of age, although patients have reportedly been as young as 4 months of age.⁹ The disease can occur in any breed, but there may be a predilection for large-breed dogs, with overrepresented breeds including German shepherds, Labrador retrievers, Doberman pinschers, and golden retrievers. Cavalier King Charles spaniels appear to have a genetic predisposition to masticatory muscle myositis.¹⁰ No gender predilection has been found.⁴

Complete physical and neurologic examinations are important to confirm that clinical signs are restricted to the muscles of mastication. Corticosteroid therapy can result in atrophy of the masticatory muscles; therefore, this should be considered in the initial evaluation. Patients should also be closely examined for evidence of trauma that could have resulted in a mandibular fracture or temporomandibular joint luxation or subluxation. Thorough oral examinations should be performed but often require heavy sedation or anesthesia. Retrobulbar masses, which may result in trismus, may cause visible swelling or drainage behind the carnassial teeth. Relatively rapid atrophy of the masticatory muscles can result from any disease that affects the trigeminal nerve, especially trigeminal neuritis and peripheral nerve sheath tumors. However, patients with trigeminal neuritis are generally nonpainful and demonstrate normal to flaccid jaw tone.

Patients presenting in the acute phase demonstrate trismus and swollen, painful masticatory muscles (Figure 2). Clinical signs are usually bilateral but may appear to be unilateral in some cases if one side is more severely

affected than the other. Clinical signs can vary in the rate of onset and severity. Ocular signs have been noted in 44% of all patients with masticatory muscle myositis, with exophthalmos noted in the acute phase because of swelling of the pterygoid muscles behind the eyes.⁹ If severe enough, exophthalmos can result in stretching of the optic nerve and subsequent blindness. Patients presenting with clinical signs of exophthalmos secondary to masticatory muscle myositis must be differentiated from those with extraocular myositis (see box on page 591).¹¹ Pyrexia and mandibular and prescapular lymphadenopathy have also been reported during the initial 1 to 3 weeks of masticatory muscle myositis.¹² Recognizing typical clinical signs of masticatory muscle myositis is essential because treatment is most successful when initiated in this phase.

Unfortunately, most owners do not recognize a problem until the chronic phase, which is characterized by marked muscle atrophy with or without persistent trismus (Figure 3). Enophthalmos may be present in the chronic phase because of atrophied pterygoid muscles.

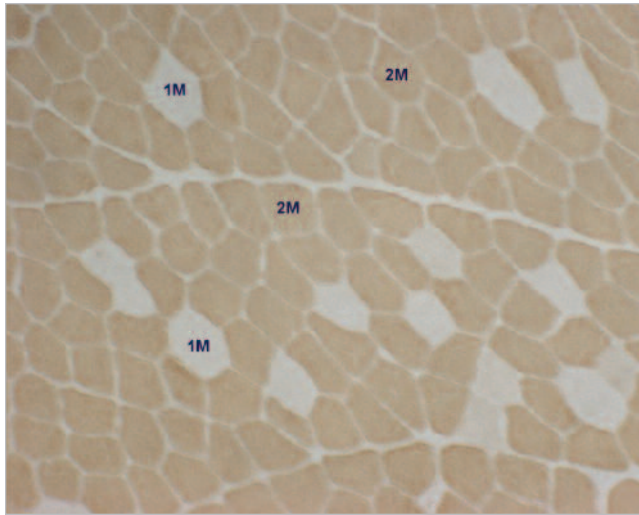
DIFFERENTIALS AND DIAGNOSTIC TESTS

Initial diagnostic testing should include a complete blood count and serum chemistry profile, including a creatine kinase (CK) level. Biochemical changes that have been documented in patients with masticatory muscle myositis include hyperglobulinemia, mild anemia, and proteinuria.⁹ Although peripheral eosinophilia has been reported, it has not been a consistent clinicopathologic finding. CK levels are frequently elevated during the acute phase but are often normal as the disease becomes more chronic. The degree of enzyme elevation, if present, is relatively less than that in patients with polymyositis because of the smaller muscle mass affected.¹³ A


Although masticatory muscle myositis may affect any canine breed, young large-breed dogs may be predisposed.

confirmatory blood test for circulating antibodies against masticatory muscle type 2M fibers is available to practitioners (see Resource box on p. 602). The immunocytochemical test, which has proven highly specific (100%) and sensitive (85% to 90%),⁴ has largely been replaced by an ELISA-based test with equal specificity and sensitivity (Figure 4).

Clinical signs compatible with masticatory muscle myositis and positive results from a 2M antibody test confirm the diagnosis. However, false-negative results may occur if immunosuppressive doses of corticosteroids have been administered for 7 to 10 days before testing and in patients with end-stage masticatory muscle myositis with loss of myofibers and fibrosis. Patients with polymyositis test negative for antibodies against type 2M fibers. A muscle biopsy is necessary to confirm a diagnosis of polymyositis.

Figure 4. Serologic assays for diagnosing masticatory muscle myositis.

Unstained fibers (light color) are type 1M, and stained fibers (brown color) are type 2M. This is a positive reaction and diagnostic of masticatory muscle myositis. An ELISA with similar sensitivity and specificity is also available.



An immunocytochemical assay in which fresh-frozen sections of normal canine temporalis muscle are incubated with serum from a dog suspected of having masticatory muscle myositis.

Because of the numerous causes associated with jaw pain and trismus (see box on this page), additional diagnostics are warranted before initiating immunosuppressive therapy for masticatory muscle myositis. Other procedures that may aid in diagnosing masticatory muscle myositis include radiology and advanced imaging, electrodiagnostics, and histologic evaluation of biopsy specimens. Skull radiographs or computed tomograms should be obtained while patients are under general anesthesia. One classic finding in masticatory muscle myositis is inability to open the jaw while the patient is under anesthesia. Other abnormalities, such as fusion of the temporomandibular joints or healed fractures, may result in similar findings but should be eliminated from the differential diagnosis by conducting imaging studies.

Electromyography (EMG) may be a useful diagnostic procedure, particularly in differentiating masticatory muscle myositis from polymyositis. Electromyographic abnormalities seen with myopathic disease include fibrillation potentials, positive sharp waves, and complex repetitive discharges. In masticatory muscle myositis, spontaneous activity is specifically found only in the masticatory muscles compared with polymyositis, in which spontaneous activity is present throughout multiple muscles.⁴ Abnormalities may be severe during the acute phase of the disease. However, EMG results may be normal in patients with end-stage disease because of

Differential Diagnosis for Trismus

- Masticatory muscle myositis
- Polymyositis (pain and reluctance to open the jaw, but no actual trismus)
- Temporomandibular joint luxation, subluxation, or fusion from chronic joint disease
- Tetanus
- Craniomandibular osteopathy
- Retrobulbar abscess
- Extraocular myositis (referred jaw pain)
- Muscular dystrophy
- Foreign body

severe atrophy or loss of muscle fibers and fibrosis. In these patients, the only change evident may be decreased insertional activity due to loss of muscle fibers. It is also important to recognize that EMG changes are nonspecific and cannot be used to differentiate between neuropathic and myopathic causes. EMG is usually conducted with the patient under general anesthesia. CK levels should be obtained before testing because inserting EMG needles transiently elevates CK values.

Evaluating a muscle biopsy can also provide diagnostic confirmation of the disease as well as additional information regarding prognosis, particularly when muscle atrophy is present and significant fibrosis is suspected. Mus-

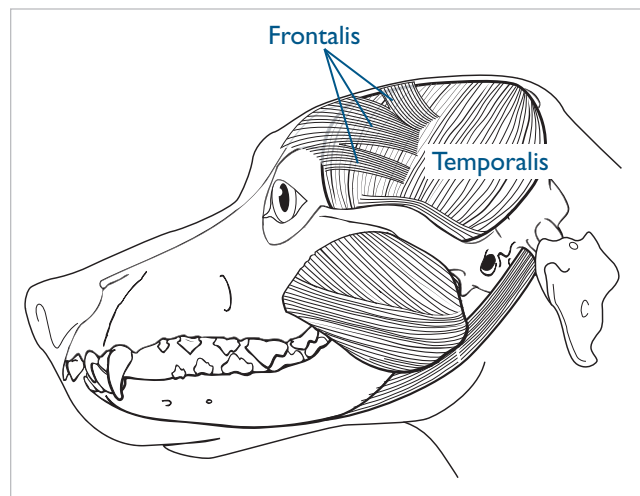
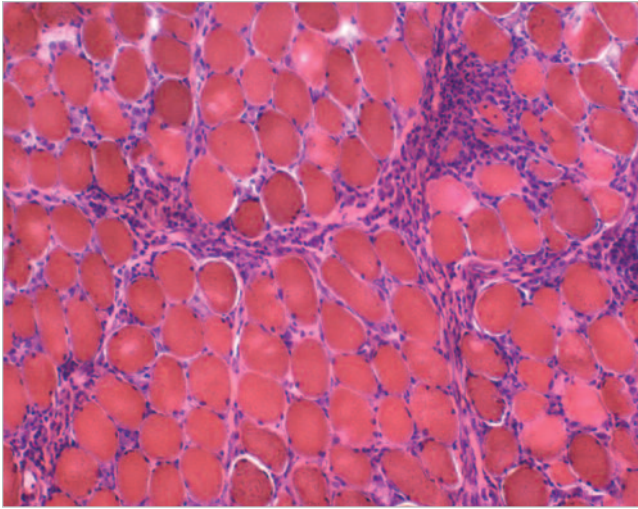


Figure 5. Biopsies are obtained from the temporalis muscle. Care should be taken not to biopsy the frontalis muscle, which overlies the temporalis, because it is not affected in masticatory muscle myositis. (Illustration by Felicia Paras)

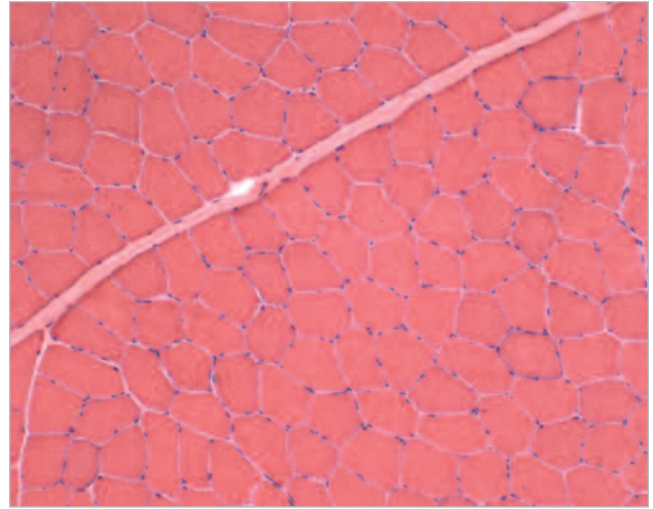
cle biopsy documents the severity of fiber loss and degree of fibrosis, which are important in determining the long-term prognosis and probable success of therapy. Muscle biopsy is a simple surgical procedure. Biopsies are typically obtained from the temporalis muscle; however, care must be taken to avoid sampling the frontalis muscle, which overlies the temporalis muscle, because it is not affected in masticatory muscle myositis (Figure 5). Biopsy of the wrong muscle is a common mistake. If generalized muscle atrophy or gait abnormalities are also present, biopsies should also be taken from limb muscles. Biopsies should be collected from sites distant from those evaluated by EMG to avoid needle-induced artifacts. In the masticatory muscles, the biopsy is generally taken from the opposite temporalis muscle. The information gained from a muscle biopsy must be weighed against the anesthesia risks associated with masticatory muscle myositis. Trismus can be severe enough that it prohibits tracheal intubation. In addition, patients may be at greater risk of aspiration pneumonia.

Biopsies are helpful in determining the stage or severity of the disease and can be diagnostic in patients in which circulating type 2M antibodies cannot be detected. In addition, biopsies are important for making a prognosis and determining the usefulness of immunosuppression. If only fibrosis is present without remaining myofibers or inflammation, the rationale for using immunosuppression therapy should be questioned. Although muscle biopsies generally show characteristic

Figure 6. Fresh-frozen hematoxylin and eosin–stained muscle biopsy specimens from the temporalis muscle of dogs.



Note the endomysial, perimysial, and perivascular distribution of the mononuclear cell infiltration in this biopsy specimen from a dog with masticatory muscle myositis.



Biopsy specimen from a normal dog.

changes, it is important to recognize that inflammatory infiltrates can have a patchy distribution and may be missed on single biopsy specimens.^{4,13,14}

Muscle biopsies obtained in the acute phase usually demonstrate a mixed inflammatory cell population, with infiltration of nonnecrotic fibers by lymphocytes and plasma cells as well as myofiber necrosis and phagocytosis (Figure 6). Contrary to the previous nomenclature of eosinophilic myositis, eosinophils are not the predominant cell type in most muscle specimens and may not even be present.⁴ In end-stage masticatory muscle myositis, the

TREATMENT

A favorable outcome in patients with masticatory muscle myositis necessitates early accurate diagnosis and appropriate therapy. Treatment is centered on aggressive immunosuppression, which is generally achieved by corticosteroid administration. The cornerstone of therapy is prednisone at 2 mg/kg PO bid during the acute phase. This dose should be maintained until maximum jaw function has been regained and CK levels have returned to normal. At that time, prednisone can be slowly tapered to the lowest every-other-day dose that

Patients with masticatory muscle myositis have a rigid jaw tone, whereas patients with trigeminal neuritis usually have a flaccid jaw tone.

predominant pathologic change is replacement of muscle fibers with fibrous connective tissue, few remaining muscle fibers, and minimal cellular infiltration (Figure 7).

If signs of systemic illness are present in a patient with generalized inflammatory myopathy, antibody titers for infectious diseases (i.e., ehrlichiosis,¹⁵ toxoplasmosis,¹³ neosporosis,¹³ leishmaniasis,¹⁶ other agents^{17,18}) should be obtained and a search conducted to detect other underlying autoimmune diseases.

abates clinical signs.¹⁴ This process should generally occur slowly over 4 to 6 months, with no more than a 50% decrease in the dose every month. After several months of decreasing the dose of prednisone, the minimal maintenance dose that abates clinical signs can be established. Although many patients require this maintenance dose for a lifetime, others can ultimately discontinue all therapy. While tapering prednisone, clinicians are advised to observe patients for relapses in clinical

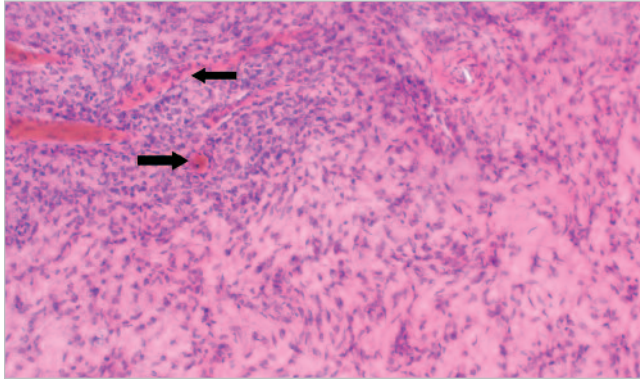


Figure 7. Fresh-frozen hematoxylin and eosin–stained muscle biopsy specimen from the temporalis muscle of a dog with end-stage masticatory muscle myositis. Note the extensive fibrosis. Only very few atrophic muscle fibers remain (arrows).

signs, which may signify a need for increased immunosuppression. Although low-dose alternate-day therapy is generally well tolerated, long-term prednisone may result in iatrogenic hyperadrenocorticism and susceptibility to infections. Owners should be prepared for resultant polyuria, polydipsia, and polyphagia associated with prednisone administration as well as the potential for steroid-induced gastric ulcers. In addition, corticosteroid therapy alone can result in masticatory muscle atrophy. If the side effects of prednisone therapy cannot

Resource

Serologic Assays for Diagnosing Masticatory Muscle Myositis

Comparative Neuromuscular Laboratory
University of California, San Diego
La Jolla, CA 92093-0709
Web: medicine.ucsd.edu/vet_neuromuscular

Therefore, regular evaluations of the complete blood count and hepatic enzymes are warranted. Cyclosporine is another immunosuppressive drug that may be used adjunctively; however, its use requires extensive therapeutic monitoring. Colchicine has also been proposed as being potentially useful because of its reported antifibrotic properties in liver disease. However, colchicine has never been proven to have antifibrotic properties in skeletal muscle.⁹

If untreated or treated inappropriately, the acute phase can progress to the chronic phase. A common problem in treating masticatory muscle myositis is using an inadequate dose of corticosteroids for too short a time. It is common for masticatory muscle myositis to respond initially to therapy, but relapses usually occur quickly if treatment is discontinued prematurely. The chronic phase is marked by severe muscle atrophy resulting from gradual replacement of muscle fibers with fibrous tissue. Corticosteroids may prove helpful in the chronic phase,

Forcible manual retraction of the jaw is contraindicated.

be tolerated, alternative immunosuppressive agents may be used.

Azathioprine is another immunosuppressive drug that can be considered in addition to traditional corticosteroid therapy. Although azathioprine is generally not included in the initial therapy for masticatory muscle myositis, it can be used in conjunction with prednisone in patients that are unable to tolerate the side effects of corticosteroids or are refractory to prednisone therapy alone. Azathioprine should be dosed at 2 mg/kg PO q24–48h and continued over several months while prednisone is slowly tapered to a maintenance dose. Thereafter, azathioprine may be slowly tapered as long as the patient does not experience a relapse. Side effects associated with azathioprine include bone marrow suppression and hepatotoxicity.

although lower doses are recommended.¹¹ The clinical application of corticosteroids in the chronic phase is based on the belief that therapy may reduce further fibrosis.

Patients experiencing significant trismus may require gruel diets to maintain adequate nutritional intake. Patients can also be encouraged to chew toys or bones to promote use of their masticatory muscles. The literature has historically recommended forcible opening of the jaw while patients are under anesthesia. Studies have found significant morbidity, including temporomandibular joint luxation and mandibular fractures, associated with this procedure, without documented improvement in clinical outcome afterward. Therefore, manual retraction of the jaw is strictly contraindicated.⁹

PROGNOSIS

The prognosis is determined by the degree of fibrosis present and the clinical response to immunosuppression. Aggressive treatment during the acute phase generally results in a good prognosis. Patients may ultimately develop muscle atrophy but often experience partial to complete remission. It is important to remember that corticosteroids alone can cause muscle atrophy and, therefore, progressive atrophy may not be indicative of worsening disease. Treatment failure and relapses usually result from inadequate immunosuppression and hasty discontinuation of corticosteroids. It is

Muscle biopsy is critical in determining long-term prognosis.

essential that patients be treated aggressively because evidence shows that patients that relapse are less likely to experience remission in the future. Patients treated in the chronic phase of the disease carry a more uncertain prognosis but can do well if extensive fibrosis does not result in persistent jaw dysfunction. Clients must be informed that jaw function may be improved but not normalized and muscle atrophy may be persistent.

REFERENCES

1. Orvis J, Cardinet III GH: Canine muscle fiber types and susceptibility of masticatory muscles to myositis. *Muscle Nerve* 4:354–359, 1981.
2. Shelton GD: Pathophysiologic basis of canine muscle disorders. *J Vet Intern Med* 1:36–44, 1987.
3. Shelton GD, Cardinet III GH, Bandman E, et al: Fiber type specific autoantibodies in a dog with eosinophilic myositis. *Muscle Nerve* 8:783–790, 1985.
4. Shelton GD, Cardinet III GH, Bandman E, et al: Canine masticatory muscle disorders: A study of 29 cases. *Muscle Nerve* 10:783–790, 1987.
5. Shelton GD: Canine masticatory muscle disorders, in Kirks RW (ed): *Current Veterinary Therapy X*. Philadelphia, WB Saunders, 1989, pp 816–819.
6. Shelton GD, Bandman E, Cardinet III GH: Electrophoretic comparison of myosins from masticatory muscles and selected limb muscles in the dog. *Am J Vet Res* 46:493–498, 1985.
7. Shelton GD, Cardinet III GH, Bandman E: Expression of fiber type specific proteins during ontogeny of canine temporalis muscle. *Muscle Nerve* 11:124–132, 1988.
8. Kresher K: Myosin: A link between streptococci and heart. *Science* 227:413–415, 1985.
9. Gilmour M, Morgan R, Moore F: Masticatory myopathy in the dog: A retrospective study in 18 cases. *JAAHA* 28:300–306, 1992.
10. Shelton GD: Unpublished data, University of California, San Diego, La Jolla, CA, 2004.
11. Carpenter JL, Schmidt GM, Moore FM, et al: Canine bilateral extraocular polymyositis. *Vet Pathol* 26:510–512, 1989.
12. Taylor S: Selected disorders of muscle and the neuromuscular junction, in Thomas WB (ed): *Vet Clin North Am* 30:59–75, 2000.
13. Podell M: Inflammatory myopathies, in Shelton GD (ed): *Vet Clin North Am* 32:147–167, 2002.
14. Mastaglia F, Ojeda V: Inflammatory myopathies: Part 2. *Ann Neurol* 17:317–323, 1984.
15. Buoro I, Kanui T, Atwell R: Polymyositis associated with *Ehrlichia canis* infection in 2 dogs. *J Small Anim Pract* 31:624–627, 1990.
16. Vamvakidis C, Koutinas A, Kanakoudis G, et al: Masticatory and skeletal muscle myositis in canine leishmaniasis (*Leishmania infantum*). *Vet Rec* 146:698–703, 2000.
17. Cooley A, Clemmons R, Gross T: Heartworm disease manifested by encephalomyelitis and myositis in a dog. *JAVMA* 190:431–432, 1987.
18. Poonacha K, Donahue J: Clostridial myositis in a cat. *Vet Pathol* 19:217–219, 1982.

ARTICLE #1 CE TEST

This article qualifies for 1.5 contact hours of continuing education credit from the Auburn University College of Veterinary Medicine. Subscribers who wish to apply this credit to fulfill state relicensure requirements should consult their respective state authorities regarding the applicability of this program. To participate, fill out the test form inserted at the end of this issue. To take CE tests online and get real-time scores, log on to www.VetLearn.com.

1. Masticatory muscle myositis is an inflammatory myopathy directed at type ____ muscle fiber.

- a. I
- b. 2A
- c. 2B
- d. 2M

2. _____ dogs are most commonly affected by masticatory muscle myositis.

- a. Young large-breed
- b. Young small-breed
- c. Old large-breed
- d. Old small-breed

3. What percentage of animals with masticatory muscle myositis has circulating autoantibodies?

- a. 50%
- b. 28%
- c. 85%
- d. 100%

4. The clinical presentation of patients with acute masticatory muscle myositis may include

- a. painful, swollen masticatory muscles.
- b. exophthalmos.
- c. submandibular and prescapular lymphadenopathy.
- d. all of the above

5. The predominant cellular infiltrate on biopsy specimens is

- a. lymphocytic or plasmacytic.
- b. macrophages.
- c. eosinophils.
- d. neutrophils.

6. CK levels are generally

- a. more elevated with polymyositis compared with masticatory muscle myositis.

- b. more elevated with masticatory muscle myositis compared with polymyositis.
- c. elevated in the acute and chronic phase.
- d. not of clinical assistance.

7. The initial immunosuppressive dose of prednisone recommended during the acute phase is

- a. 1 mg/kg/day PO.
- b. 0.25 mg/kg PO bid.
- c. 2 mg/kg PO bid.
- d. 0.5 mg/kg PO bid.

8. Therapeutic failure when treating masticatory muscle myositis is generally due to

- a. an inadequate steroid dose.
- b. an inadequate duration of immunosuppressive therapy.
- c. failure to treat during the acute phase.
- d. all of the above

9. A negative result using the 2M antibody test is generally not due to

- a. poor sensitivity and specificity.
- b. previous use of immunosuppressive therapy before testing.
- c. end-stage disease.
- d. polymyositis.

10. Additional therapy for patients with masticatory muscle myositis should not include

- a. gruel diets.
- b. manual retraction of the jaw.
- c. chew toys.
- d. managing side effects associated with long-term prednisone therapy, such as urinary tract infections.