

The Principles of Surgical Oncology: Surgery and Multimodality Therapy*

» Julius M. Liptak, BVSc, MVetClinStud, FACVSc, DACVS, DECVS
Alta Vista Animal Hospital
Ottawa, Ontario, Canada

Abstract: Surgery to treat cancer is one of the most common procedures performed in small animal practice. Clinicians should identify potential intraoperative risk factors, such as blood loss and hypotension, and be prepared to address these complications. Of the surgical doses that can be used to resect tumors, wide resections are preferred, although marginal resection is acceptable if the tumor is sensitive to radiation and adjunctive radiation therapy is planned. Other types of surgical procedures used in oncology include preventive, palliative, and second-look procedures, as well as minimally invasive laparoscopy and thoracoscopy to assess treatment efficacy. Depending on the tumor type and metastatic potential and the completeness of excision, adjunctive radiation therapy and chemotherapy should also be considered.

At a Glance

- ▶ Perioperative Management
Page E1
- ▶ Anesthetic Management
Page E2
- ▶ Curative-Intent Surgery
Page E2
- ▶ Intraoperative Management
Page E4
- ▶ Histopathology
Page E7
- ▶ Postoperative Management
Page E10
- ▶ Multimodal Management
Page E10
- ▶ Other Types of Oncologic Surgery
Page E12

The first surgery provides the best chance for a cure in an animal with a tumor. Therefore, it must be planned carefully to ensure that either the mass is excised completely or the remaining tumor cells can be treated with adjunctive therapy. Surgical planning depends on knowledge of tumor type, clinical stage, and expected biologic behavior.¹ If these are not known, then surgery should be planned to encompass all possible eventualities, including intraoperative cytology or frozen-section histopathology.¹ There are four levels of aggressiveness (doses) for surgical resection: radical, wide, marginal, and debulking.² Incompletely excised benign and malignant tumors will recur. Recurrent tumors are often more locally invasive due to altered vascularity and local immune responses, and the destruction of normal tissue planes makes subsequent surgeries more difficult and extensive.^{1,3}

Perioperative Management

Before definitive surgical resection, appropriate diagnostic and staging tests should be conducted to assess whether the animal is a good anesthetic and surgical candidate and to determine the surgical plan and dose. Comorbid conditions, whether related to the primary tumor (e.g., vomiting and dehydration secondary to a gas-

trointestinal tumor) or unrelated (e.g., renal, hepatic, cardiac disease), increase the risk of surgical morbidity and mortality and may affect the surgical dose and postoperative management.^{1,3} Chemotherapy, radiation therapy, and surgery can be altered, incorporated, or eliminated on the basis of comorbid conditions.¹ For example, neurologic disease is a contraindication to limb amputation; hence, limb-sparing surgery may be preferable for a dog with appendicular osteosarcoma (OSA) and concurrent neurologic disease. For postoperative management, cardiotoxic (e.g., doxorubicin) and nephrotoxic (e.g., cisplatin) chemotherapy agents should not be administered to dogs with preexisting cardiomyopathy or renal disease, respectively.

Anemia

Comorbid conditions are not a contraindication to surgery with appropriate preoperative management to reduce the associated physiologic stresses.³ For instance, anemia is relatively common in animals with cancer, especially those with advanced disease.⁴ Anemia may be caused by chronic disease, blood loss, or myelophthisis.¹ In people, it is associated with poorer survival times and local tumor control rates.⁴ The administration of blood products has been recommended to improve oxygen-

*A companion article, "The Principles of Surgical Oncology: Diagnosis and Staging," is also available on CompendiumVet.com.

carrying capacity and potentially decrease complications associated with hypotension and impaired wound healing.⁵ However, the necessity and timing of blood transfusions have not been defined in veterinary medicine. In general, the administration of blood products may not be required in animals with chronic anemia, whereas transfusions should be considered in animals with acute intraoperative blood loss (i.e., >25% of blood volume or packed cell volume <20%) and hypotension (mean arterial pressure <80 mm Hg or systolic arterial pressure <100 mm Hg).⁶ To minimize the risk of transfusion reactions, cross-matching or blood typing should be conducted before blood products are administered.⁶

interpretation, and may potentiate metastasis.³ Depending on the preoperative condition of the patient, the presence of paraneoplastic syndromes, and the tumor type and location, the surgeon should be prepared to address possible intraoperative and postoperative complications, such as the following:

- ▶ Hypotension (mean arterial pressure <80 mm Hg or systolic arterial pressure <100 mm Hg), which can be treated with a bolus of crystalloid fluid, infusion of natural or synthetic colloidal solution, and administration of vasopressor or inotropic drugs
- ▶ Hemorrhage, which is managed with immediate hemostasis (e.g., vascular clamps, hemoclips), and the metabolic consequences of acute anemia, for which blood products are administered
- ▶ Pain, which should be preempted by administration of local, regional, or systemic analgesic drugs before, during, and after surgery (intraoperative analgesia has the added benefit of decreasing inhalant anesthetic requirements and the subsequent risk of hypotension)
- ▶ Respiratory compromise, which can be managed with ventilatory support and oxygen therapy

Anesthetic monitoring is important for the early identification and correction of these complications. Basal anesthetic monitoring should measure the depth of anesthesia and efficacy of ventilation and tissue perfusion using a variety of monitors, such as an esophageal stethoscope, esophageal or rectal thermometer, direct or indirect blood pressure monitors, electrocardiography, end-tidal carbon dioxide monitor, capnography, and pulse oximetry. A centrifuge and a blood gas monitor should be available for assessment of packed cell volume, total solid and electrolyte levels, and blood gas parameters.

Curative-Intent Surgery

The aggressiveness of surgical resection (surgical dose) is categorized as radical, wide, marginal, or intralesional (or debulking). These categories were first proposed for musculoskeletal tumors but have since gained wide acceptance for all solid tumors.¹⁰ The most common mistake in surgical oncology is to use too low a surgical dose, particularly from fear of being unable to close the resultant

QuickNotes

Surgical treatment of cancer is categorized according to the aggressiveness of the approach, with wide resections recommended for the treatment of most tumor types if feasible. Marginal resection is acceptable if it is planned preoperatively and combined with adjunctive radiation therapy.

Analgesia

Tumor-associated pain is rare with non-metastatic tumors, more common with early metastatic tumors, and almost universal with advanced metastases.⁷ Pain is caused by mechanical or chemical stimulation of nociceptors by the tumor, diagnostic or therapeutic procedures, or the treatment itself.⁷ The deleterious effects of pain on outcome are well documented and can be ameliorated with the administration of analgesic agents (NSAIDs, partial agonists or antagonists, opioids, α_2 -agonists, *N*-methyl-D-aspartate [NMDA] antagonists) through local, regional, or systemic routes or alternative therapies such as acupuncture.⁷

Other Considerations

Enteral nutrition and antibiotic prophylaxis are recommended when appropriate. These therapies are described in detail elsewhere, including the indications for and techniques, feeding protocols, and complications of enteral nutrition.⁸ The indications, antimicrobial selection, and timing of administration for antibiotic prophylaxis are likewise addressed in the literature.⁹

Anesthetic Management

General anesthesia is usually required for definitive surgical resection, although some tumors may be excised using a combination of sedation and local or regional anesthesia. Local anesthetics should not be administered intratumorally, as this distorts tumor architecture, increases the difficulty of histopathologic

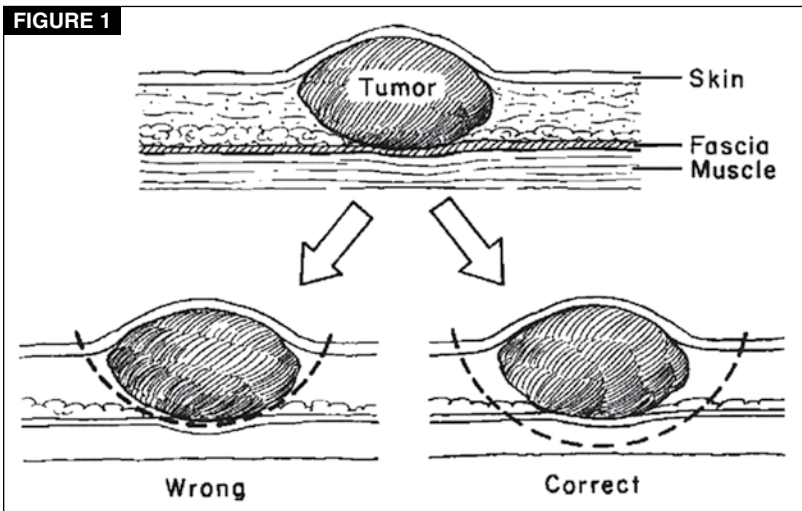
defect. This hazard can be minimized through the use of sterile surgical markers to delineate margins before incision and assist in orienting the surgeon. As two of the most prominent veterinary surgical oncologists, Drs. Brodey and Withrow, have stated, “It is better to leave a wound open [...] than to leave tumor cells remaining.”²

Wide and Radical Resections

Wide and radical resections are considered curative-intent surgeries aimed at resecting macroscopic and microscopic disease, including biopsy tracts, thus preventing local tumor recurrence and improving overall survival times. Wide or radical surgical resection is recommended to manage most solid tumors.

For wide and radical resection of tumors, a margin of normal-appearing tissue should be excised en bloc with the gross tumor to eradicate any microscopic extension of the tumor. Surgical margins should be determined on the basis of the type, grade if appropriate (e.g., mast cell tumor [MCT]),¹¹ biologic behavior, and anatomic location of the tumor and the barrier provided by surrounding tissue.^{1,3,10} Precise guidelines for appropriate tumor margins have not been defined for most tumor types. Most surgeons use predetermined distances depending on tumor type, but there is evidence that tumor size also influences the extent of microscopic tumor extension, with larger tumors of the same histologic type having greater microscopic extension and hence requiring larger margins than smaller tumors.¹²

Margins are three-dimensional, so lateral and deep margins must be considered when planning resections (FIGURE 1).² Lateral margins are determined by tumor type and biologic behavior. For example, 1-cm lateral margins are recommended for benign tumors and most malignant carcinomas, whereas 3-cm lateral margins are required for soft tissue sarcomas (STs).² For MCTs, lateral margins are also determined by histologic grade, with 1-cm lateral margins sufficient for grade I MCTs and 2-cm lateral margins for grade II MCTs.¹¹ Deep margins are determined by natural tissue barriers, as 1- to 3-cm deep margins are often not possible in regions such as the extremities and trunk. Fat, subcutaneous tissue, muscle, and parenchymal tissue do not provide a barrier to



Wide resection of tumors involves adequate lateral and deep margins. The width of the lateral margins is determined by the tumor type and ranges from 1 cm for benign tumors and carcinomas to 3 cm for soft tissue sarcomas and 5 cm for vaccine-associated sarcomas. Deep margins are not determined by tumor depth, but rather by tumor-resistant fascial layers. A minimum of one fascial layer should be included in the resection. The deep margin is the most common site of failure. (Reproduced with permission from Withrow SJ, MacEwen EG, eds. *Small Animal Clinical Oncology*. 3rd ed. Philadelphia: Saunders; 2001:72.)

tumor invasion.¹³ Connective tissues, such as muscle fascia and bone, are resistant to neoplastic invasion and provide a good natural tissue barrier.¹³ Hence, deep margins should include a minimum of one fascial plane. Two fascial planes are recommended for surgical resection of vaccine-associated sarcomas (VASS).¹⁰ Lateral and deep margins should be greater if the tumor is invasive, recurrent, or inflamed. Tumors (particularly STs) should never be “shelled out” because they are often surrounded by a pseudocapsule of compressed, viable neoplastic cells; these cells must also be removed completely.^{2,3,14}

Radical resection is defined as the removal of a body part. This is occasionally required for complete excision of a tumor, such as splenectomy for splenic hemangiosarcoma (HSA) and limb amputation for appendicular OSA.

Marginal Resection

Marginal resection is defined as the incomplete excision of a tumor with residual microscopic disease. Marginal resection can be either planned or unplanned. Planned marginal resection is used when the tumor type is known based on preoperative biopsy. It is a useful limb-sparing technique for MCTs and STs of the distal extremities when combined

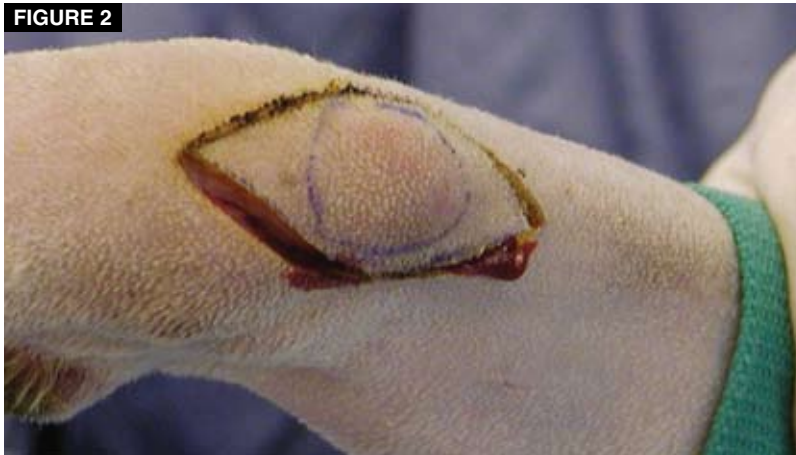

FIGURE 2
Planned marginal resection of an STS on the distal limb of a dog. Marginal resection results in removal of the measurable tumor burden, but microscopic tumor cells remain in the surgical wound. Adjunctive radiation therapy is required to minimize the risk of local tumor recurrence. Planned marginal resections result in smaller surgical wounds and hence smaller radiation fields with less morbidity compared with surgery alone but equivalent tumor control and survival times. Furthermore, limb function is preserved.

with postoperative radiation therapy.^{15,16} Limb amputation is usually required for definitive surgical resection of tumors in these locations. Marginal resection removes the gross tumor burden and preserves limb function without compromising wound closure (**FIGURE 2**). Radiation therapy is more effective against microscopic disease than against gross tumor burdens, and local tumor control and overall survival times with marginal resection and postoperative irradiation of extremity STSs are not significantly different from those with definitive surgical resection.¹⁵⁻¹⁷

Unplanned marginal resections occur when excisional biopsies performed without prior knowledge of tumor type result in incomplete excision. Unplanned marginal resections should be avoided by conducting appropriate preoperative biopsy, clinical staging, and surgical planning. Unplanned resections are associated with a higher risk of incomplete excision and can have a significant negative impact on future treatment by either increasing the aggressiveness of therapy required to appropriately manage the tumor or making further treatment impossible.¹⁷⁻²¹ Local tumor control rates are significantly reduced after unplanned resections.²⁰

There are four techniques for managing unplanned marginal resections: no treatment, staging resection of the surgical wound, wide

resection of the surgical wound, and combination with radiation therapy. The no-treatment option may be effective for low-grade tumors that may not recur²² or for tumor types that do not have a significant impact on quality of life, such as some cutaneous STSs. Staging resection of surgical wounds is an intermediary step used to determine whether tumor cells are present in the surgical field and, if so, the need for further therapy. Staging resection involves excision of the surgical wound with margins of 10 mm or less (**FIGURE 3**). Anecdotally, despite histologic evidence of incomplete resection after the first surgery, approximately 75% of MCTs^a and STSs have no evidence of residual tumor following staging resection and, hence, do not require further treatment.^{17,23,24} Staging resections can therefore be used to determine whether animals should be subjected to further expensive, time-consuming, and potentially harmful treatments. Aggressive surgical resection, using margins appropriate for the tumor type, or adjunctive treatment with radiation therapy is required for most tumors after unplanned marginal resection or histologic evidence of residual tumor burden on staging resection.^{10,18,19,21}

Debulking Surgery

Debulking surgery is defined as the incomplete resection of a tumor with residual gross disease.² Debulking surgery is rarely an acceptable treatment for neoplastic diseases because tumor regrowth is usually rapid, and the presence of a macroscopic tumor burden makes adjunctive treatments less effective.¹⁷

Intraoperative Management Preparation

Following induction of general anesthesia, the surgical site should be widely clipped to facilitate wound closure for more aggressive or reconstructive procedures, if needed.¹ For skin tumors, gentle skin preparation is important because vigorous scrubbing can result in tumor cell exfoliation and an increased risk of metastasis.^{1,3}

Technique

Surgical technique is an important consideration during tumor resection because of the

^aBacon NJ, Liptak JM, Withrow SJ. Unpublished data.

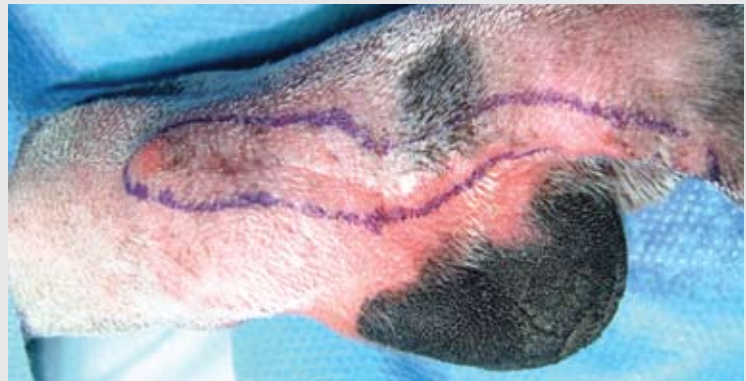
effect on tumor control and surgical morbidity. Scalpel blades should be used, particularly on skin and hollow organs, because they are the smoothest and least traumatic cutting instruments.^{1,3,23} The proper use of scalpels reduces tissue trauma and preserves vascular supply. Scissors are useful to separate fascial planes and in body cavities where scalpel blades may be impractical or hazardous.² Tissue should be placed under moderate tension when dissecting or incising to permit more accurate dissection, decrease tissue trauma and hemorrhage, and improve visualization of normal tissue planes and vascular and lymphatic vessels.²³

Hemostasis, with prompt electrocoagulation or ligation of arterial, venous, and lymphatic vessels, is important to prevent the release of tumor emboli into the circulation (especially for tumors with a good vascular supply, such as splenic and lung tumors) and minimize the risk of postoperative complications such as hematomas.^{2,14,25,26} With proper technique, electrosurgery and laser surgery can be useful for hemostasis, but thermal necrosis can delay wound healing, decrease resistance to infection, and distort and damage tissue samples, making assessment of surgical margins difficult or impossible.^{1,3,27} Ligatures or hemoclips can be used for hemostasis, but care should be used when placing these devices because inadvertent spread of cancer cells has been reported with ligatures too close to and cutting into the tumor.¹⁴ If an exploratory celiotomy or thoracotomy is being performed, the entire cavity should be examined to determine the extent of the tumor. The liver, kidneys, omentum, and regional lymph nodes are common sites of metastasis in dogs with splenic HSA, and the hilar lymph nodes should be palpated and aspirated in cats and dogs with lung tumors.^{1,3}

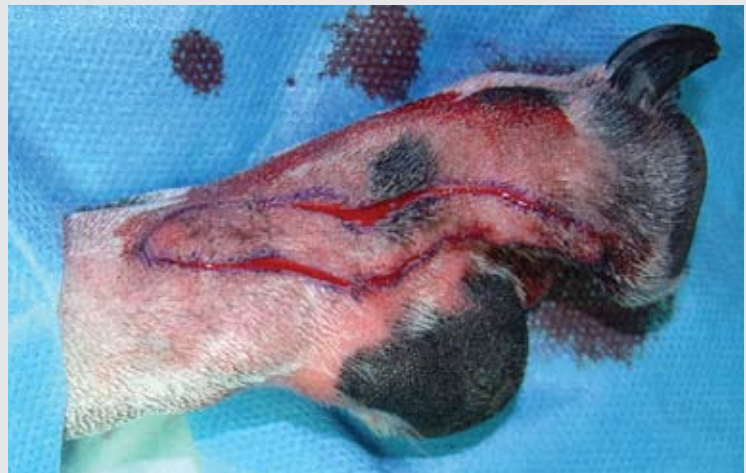The surgical handling of a tumor is similar to that of an abscess: care is required to prevent exfoliation of cells and local recurrence.¹⁻³ Normal tissue must be protected from seeding with tumor cells resulting from inappropriate planning or handling. The tumor should be isolated with moistened laparotomy sponges and, if required, manipulated with stay sutures or atraumatic surgical instruments placed in adjacent normal tissue.¹⁴ Directly grasping the tumor with instruments can result in tissue fragmentation and exfoliation of tumor cells

FIGURE 3

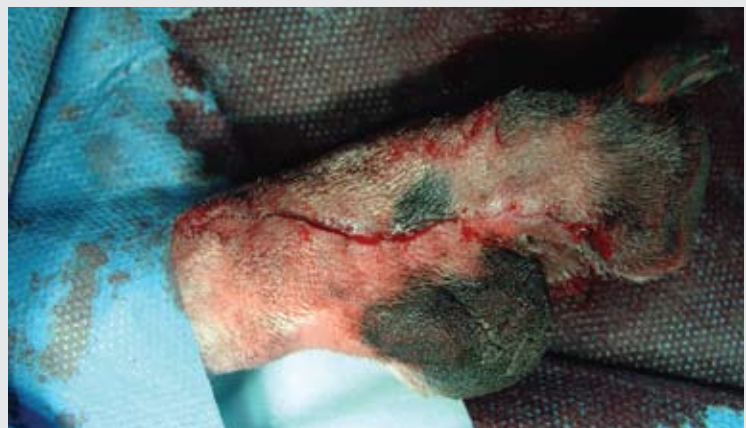Staging resection of a scar from an incompletely resected mast cell tumor.



Margins of <10 mm around the surgical scar are marked intraoperatively with a sterile marking pen.



The surgical scar is resected along the marked margins.



The surgical wound is closed primarily with minimal tension.

The aim of staging resections is to determine whether there is evidence of tumor cells in the surgical scar of incompletely resected tumors and, thus, whether further treatment is required, without having a significant impact on the ability to close the wound or on quality of life.

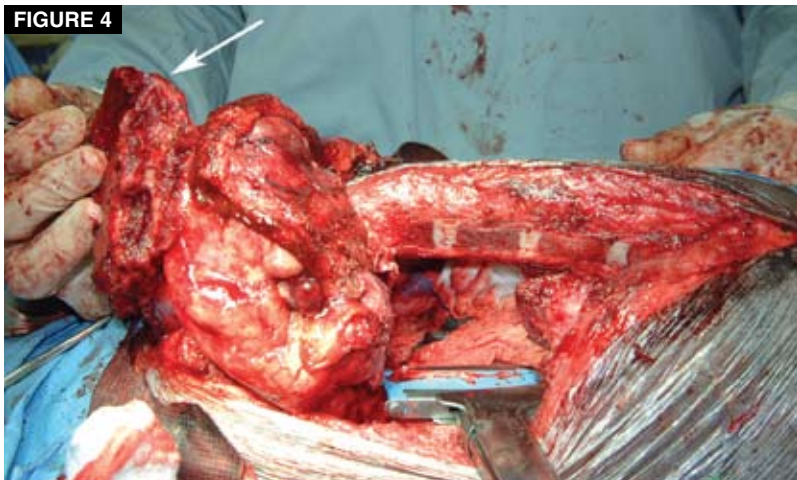


FIGURE 4
A segment of chest wall (ribs and sternum) has been resected en bloc with an invasive thymoma in a dog (arrow). Tumor adhesion to adjacent structures may represent neoplastic invasion, so en bloc resection is recommended in such cases, if feasible.

into the surgical wound, as can inadvertent penetration of the tumor capsule with sharp instruments such as Senn retractors.¹⁴ Careful, indirect intraoperative handling substantially improves 5-year survival rates in people.²⁶ Stay sutures can also be used as markers to orient the pathologist and identify suspicious surgical margins.²⁸

Tumors can adhere to adjacent structures without gross evidence of invasion, but these adhesions represent direct tumor invasion in many cases.²⁵ As a result, structures adhered to tumors should be resected en bloc, if possible, to minimize the risk of incomplete resection and local tumor recurrence³ (FIGURE 4). For example, pericardiectomy and lung lobectomy should be performed for rib tumors adherent to the pericardium and lung lobe, respectively.

Suture selection is important in surgical oncology because multifilament suture materials are associated with an increased risk of local tumor recurrence as a result of tumor cells being trapped in the interstices of the braided material.²⁹ Monofilament suture material and staples are preferred for ligation and wound closure.^{25,30} Although most chemotherapy agents do not clinically affect wound healing,³¹ it is prudent to use synthetic monofilament absorbable suture materials that preserve their tensile strength for prolonged periods, such as polydioxanone or polyglyconate, if postoperative chemotherapy is planned. If postoperative radiation is planned,

the margins of the surgical field can be marked with radiopaque surgical clips to assist the radiation oncologist in planning the radiation field.³²

The role of wound lavage is controversial, particularly within body cavities. Wound lavage may dilute residual exfoliated tumor cells and decrease the risk of local tumor recurrence, or it may disseminate the exfoliated cells throughout the lavaged cavity.³ In animal models, tumor cells have been shown to adhere to specific cellular receptors, and wound lavage has minimal benefit following this event.²⁹ However, wound lavage is recommended to prevent tissue dehydration and to remove blood clots and foreign material from the wound or body cavity.^{2,3} Furthermore, cytology of lavage fluid following gastric tumor resection in people can provide important information on tumor recurrence and prognosis.³³

Drains should not be used during oncologic surgery because they further disrupt deep and lateral tissue planes distant to the surgical field, thus seeding tumor cells and extending margins if the resection is incomplete. Drains do not compensate for poor hemostatic technique. However, they can be used to manage postoperative complications, such as seroma formation, once the surgical margins have been determined. Similarly, it is preferable to avoid reconstructive surgery, particularly pedicle and axial pattern flaps, at the time of initial tumor resection. If postoperative radiation is planned and drains or tissue flaps are used during primary surgical resection, they should be placed to minimize the size of the radiation field.^{1,3}

Intraoperative Tumor Disruption

Intraoperative disruption of the tumor results in contamination of the surgical field and conversion of a potentially curative resection to a large biopsy procedure. If the tumor margins are compromised, the exposed surfaces should be electrocoagulated, fulgurated, or sutured; the wound should be copiously lavaged; and gloves, instruments, and drapes should be changed.^{1,3,18} Because the entire wound is now effectively seeded with tumor cells, it should be resected with appropriate margins if possible. If this is not possible, then all evidence of gross disease should be resected and adjunctive radiation therapy administered postoperatively.¹⁸

Wound Closure

Primary wound closure is preferred, but the surgical dose should not be compromised because of concerns about wound closure.² There are a number of options for wounds that cannot be closed primarily. I prefer to manage these as open wounds until histopathologic analysis reveals whether the tumor has been completely or incompletely resected. If the tumor has been incompletely excised, then further resection is required. Once there is no histologic evidence of tumor, pedicle or axial pattern flaps can be safely used to reconstruct the soft tissue defect (FIGURE 5). If reconstructive surgery is used at the time of tumor resection and excision is incomplete, then both the flap donor site and tumor resection site are considered contaminated. This has been reported in 39% of dogs in which an axial pattern flap was used to reconstruct a defect resulting from tumor excision.^{34,35} In these cases, further surgery and/or radiation therapy may be either more extensive or not possible, depending on the location and extent of the contaminated incisions. However, some surgical oncologists perform tumor resection and reconstruction in the same procedure.

The most useful reconstructive techniques involve the use of tension-relieving procedures (e.g., suture patterns, releasing incisions), local pedicle flaps (e.g., advancement flaps, transposition flaps, flank fold flaps), axial pattern flaps (e.g., thoracodorsal and caudal superficial epigastric axial pattern flaps), and free meshed skin grafts. If reconstructive procedures are performed at the same time as tumor resection, it is imperative that gloves and surgical instruments be changed for the reconstructive procedure to minimize the risk of tumor seeding, particularly when reconstructive surgery involves distant sites, such as releasing incisions and skin grafts. A knowledge of these techniques before major reconstructive surgery reduces morbidity and decreases the risk of compromising the excision margins.³

Histopathology

The entire resected mass should always be submitted for histopathologic assessment of tumor type, grade if appropriate, and surgical margins. This knowledge is essential so that the risk of local tumor recurrence and metastasis can be determined, further treatment

can be planned if necessary, and the owners can be advised of the prognosis.¹⁸ Even if a preoperative biopsy has been performed, histopathologic confirmation is still required because biopsies only sample a small region of the tumor and may not be representative of the true tumor type because of tumor heterogeneity.

The entire tumor should be fixed in 10% buffered formalin at one part tissue to 10 parts formalin.^{1,36,37} Large tumors may need to be sliced into sections more than 1 cm thick to facilitate adequate fixation, but to maintain the ability of the pathologist to orient the sample and assess margins, the slicing should not be full-thickness through the tumor.³⁷ Improper fixation (e.g., less than 1:10 in 10% formalin) produces tissue artifacts and can result in misdiagnosis.³⁸ If the entire tumor cannot be fixed, then samples of the tumor and complete lateral and deep margins should be fixed separately.³⁷ If hemoclips are used during dissection of the tumor, they should be removed before sample submission to avoid damage to microtomes.³⁶ Tumors should be labeled and submitted to a veterinary pathologist with a detailed history of clinical and surgical findings, including anatomic location, size, shape, texture, and relationship to surrounding structures.³⁷ If required, a drawing of the specimen and labeling of margins may assist the pathologist in selecting the most appropriate area of the tumor to sample. If the histopathologic results do not correlate with either the preoperative biopsy or the clinical presentation, the case should be discussed with the pathologist and, if required, resectioning, special stains, or a second opinion from another pathologist should be requested.^{3,36-38}

Histologic Grade

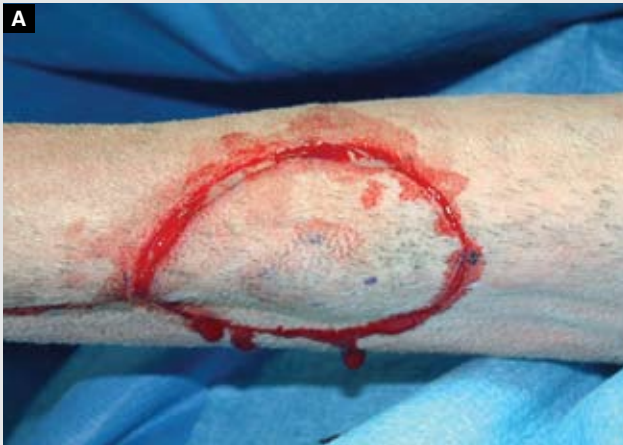Histologic criteria are used to determine whether a tumor is benign or malignant and, if malignant, histologic grade. Cellular features of benign masses include low nuclear-to-cytoplasmic ratio, uniform nuclear size and shape, and low mitotic rate.^{37,38} Histologic features do not necessarily correlate with biologic behavior because some benign tumors can be locally aggressive, such as infiltrative lipomas and oral acanthomatous epulides. Histologic features of malignant tumors include poor cellular differentiation, high cellularity, high

QuickNotes

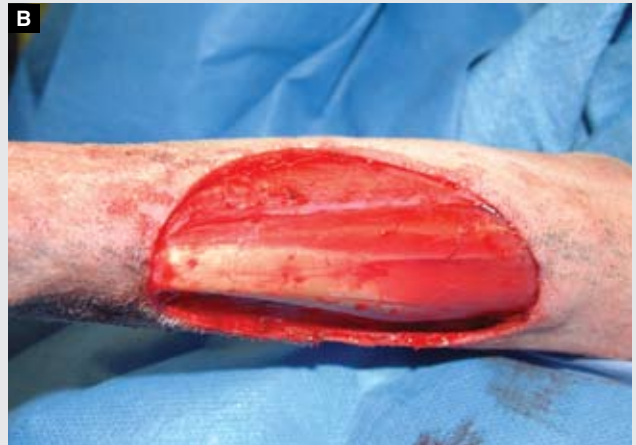The first surgery provides the best chance of a cure for animals with cancer.

FIGURE 5

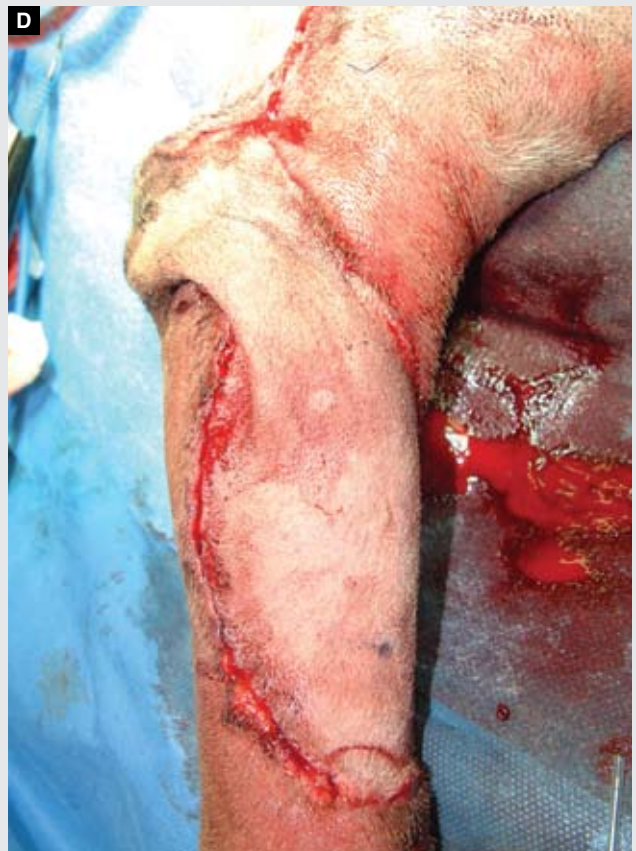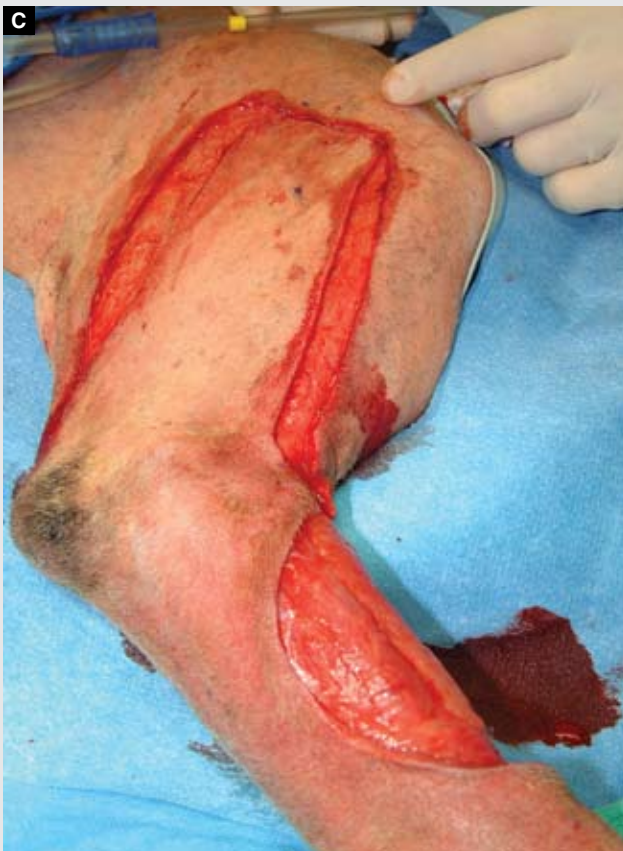Surgical removal of an MCT from the limb of a dog.



A grade II MCT is resected with 2-cm margins.



B The large residual defect cannot be closed primarily. This defect was managed as an open wound until histopathologic confirmation of complete excision. The initial resection was incomplete. A second surgery with additional lateral resection and deep muscle biopsies resulted in complete tumor excision.



C After confirmation of complete resection following the second surgery, reconstructive surgery with a transposition flap was used to close the defect. If this flap had been used initially, the donor and recipient surgical wounds would have both been considered contaminated because of incomplete tumor excision. Limb amputation or extensive radiation, with the associated increase in cost and morbidity, would have been required for management of the contaminated scar.



FIGURE 6
The lateral and deep margins of a tumor are marked with dye to assist the pathologist in determining completeness of excision. The completeness of excision is important in planning postoperative treatment regimens.

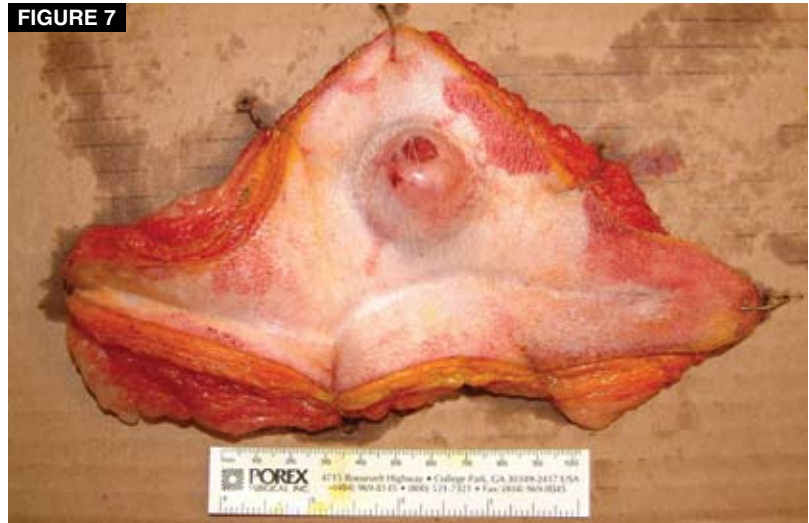

FIGURE 7
A tumor pinned out to its original dimensions. This practice minimizes the effect of specimen shrinkage on assessment of completeness of excision and clean but close excisions.

nuclear-to-cytoplasmic ratio, large or multiple nucleoli, high mitotic rate, and variations in nuclear size (anisokaryosis), nuclear shape, and cytoplasmic size (anisocytosis).^{37,38}

Histologic grading is valuable for determining treatment plans and prognosis for some tumors.³⁷⁻³⁹ However, surgical pathologists do not uniformly agree on the use of grading schemes, and grading schemes are not available for all tumors.³⁸ Grading schemes have been reported and validated for feline lung tumors and mammary gland carcinomas, as well as for canine MCTs, STSs, mammary gland carcinomas, cutaneous and ocular melanomas, lung tumors, splenic HSAs, splenic nonhematogenous and nonlymphatous sarcomas, synovial cell sarcomas, transitional cell carcinomas, appendicular and mandibular OSAs, multilobular osteochondrosarcomas, squamous cell carcinomas of the tongue, and lymphomas. A histologic grade should be requested from the pathologist if one of these tumors is diagnosed.³⁹

Margins

Pathologists examine the histologic characteristics of tumor margins to determine the

absence or presence of neoplastic cells.^{37,40,41} Margin assessment can be facilitated by inking the margins (FIGURE 6) and pinning out the tumor to its original dimensions (FIGURE 7). The risk of local recurrence is not completely eliminated even with histologic evidence of complete tumor resection because pathologists can only examine a representative sample and not the entire tissue margin.^{11,36,37,41} An 8% local recurrence rate is reported after apparently complete resection of truncal STSs in dogs.²²

The tumor margins should be marked with sutures or dye to assist the pathologist with orientation.^{10,37,40,42} Alternatively, particularly for large tumors, the surgical margins can be submitted separately.^{28,36,43} Marking the tumor edges with dye (ink) is a simple method for determining whether a tumor has been completely or incompletely resected. Ink is retained during tissue processing and helps the pathologist to avoid mistaking margins resulting from trimming or shrinkage for true surgical margins.³⁷ Commercially available inking kits, alcian blue, and India ink in acetone are all appropriate for identifying surgical margins.^{42,43} The specimen should be air dried for 5 to 20 minutes before it is placed in formalin.^{10,36} Ink should not be used when hormone receptor assays are anticipated because false-positive results are common.^{28,42}

Ideally, the tumor should be pinned out on cardboard to its original dimensions before

fixation. During fixation, a tumor sample can shrink by up to 38%, depending on the location from which it was taken and the inclusion of muscle and fascia in the sample.⁴⁴ This shrinkage does not influence whether the tumor has been completely resected, but it can affect the interpretation of the completeness of resection. Pathologists often comment on whether a tumor was resected “clean” or “clean but close,” with the latter variably defined as tumor cells being within 1 to 10 mm of the surgical margin.^{37,44,45} If the tumor sample is not pinned out to the original dimensions, sample shrinkage may result in the resection being erroneously classified as clean but close rather than clean, causing unnecessary decision-making dilemmas. Unlike the management of animals with completely and incompletely resected tumors, the management of patients with tumors resected clean but close is controversial and has not been defined.^{23,45}

QuickNotes

Tumor resection involves excision with adequate lateral and deep margins. The deep margins (which usually consist of fascial layers) are the most common site of failure to achieve complete excision.

Postoperative Management

In the immediate postoperative period, cats and dogs should be monitored for anesthetic and surgical complications specific to the procedure performed. The type, route, and duration of analgesia are determined by the aggressiveness of the surgical procedure and response to therapy and may involve local anesthesia, NSAIDs, partial agonists or antagonists, NMDA antagonists, or opiates. Nutritional support (enteral or parenteral) should be started if required.

After recovery from surgery, regular follow-up evaluations are important so that local tumor recurrence and distant metastasis can be detected early and salvage therapy successfully instituted. The intervals between repeat examinations and the diagnostic tests to be conducted at each examination depend on the tumor type, clinical stage, and current treatments (e.g., adjuvant chemotherapy, radiation therapy). In general, animals should be examined monthly for the first 3 months, then quarterly for 12 months, and every 6 to 12 months thereafter. History, physical examination, and palpation and examination of the surgical site and regional lymph nodes should be performed in all cases. Evaluation for metastasis depends on the tumor type and can include three-view thoracic radiography, abdominal ultrasonography, blood tests, and other imaging modalities.

Owners should be encouraged to allow necropsy to provide accurate outcome data and critical evaluation of the limitations of treatment. Critical review enables consideration of the inclusion or exclusion of diagnostic tests and treatment options if local or systemic treatments for a particular tumor type frequently fail. For instance, postmortem examinations revealed that using limb amputation alone to treat most dogs with appendicular OSA failed because of metastatic disease. When chemotherapy was added to the treatment protocol, the time to onset of metastatic disease increased and survival times significantly improved.¹

Multimodal Management

Multimodal therapy comprises some combination of surgery, radiation therapy, chemotherapy, immunotherapy, and alternative therapies. This approach is aimed at maximizing the benefits of treatment and the potential for cure while minimizing adverse effects.^{1,2} The timing of these therapies relative to surgical resection is an important consideration when planning treatment regimens because neoadjuvant (before surgery) and adjuvant (after surgery) administration have specific advantages and disadvantages (**TABLES 1 AND 2**).

Neoadjuvant therapy is rarely used in veterinary oncology, except for VASs. Neoadjuvant therapies, particularly radiation therapy, can reduce tumor size, decrease the risk of satellite and skip metastases, and eliminate microscopic tumor extension into normal tissue.⁴⁶ As a result, neoadjuvant radiation therapy can decrease the surgical dose required for complete tumor resection, permit resection of previously inoperable tumors, and reduce the incidence of tumor seeding and local tumor recurrence.^{1,20,46} Radiation therapy is theoretically more effective in the neoadjuvant setting because an unimpaired vascular supply to the tumor causes the cells to be better oxygenated and more radiosensitive.^{20,47} However, radiation therapy has deleterious effects on the regional vascularity and is associated with a significantly higher rate of delayed wound healing and other wound complications compared with adjunctive radiation therapy, particularly with doses exceeding 4 Gy/fraction and tumors not involving the head and neck.^{47,48}

Adjuvant therapies are aimed at eliminating

TABLE 1 Timing of Radiation Therapy Relative to Surgery^{47,48}

Timing	Advantages	Disadvantages
Preoperative	<ul style="list-style-type: none"> ▶ Preservation of blood supply to the tumor decreases the risk of radioresistant hypoxic tumor cells ▶ Smaller radiation field decreases exposure of surrounding tissue to radiation ▶ Decreased risk of disseminating tumor cells during surgery ▶ Reduction in tumor size facilitates surgical resection 	<ul style="list-style-type: none"> ▶ Delayed wound healing ▶ Increased risk of wound dehiscence
Intraoperative	<ul style="list-style-type: none"> ▶ Visualization of tumor bed and accurate delivery of radiation dose ▶ Decreased exposure of adjacent normal tissue to radiation ▶ Ability to deliver a larger fractional dose 	Special facilities required
Postoperative	<ul style="list-style-type: none"> ▶ No delay in definitive surgery ▶ Wound healing is not delayed ▶ Clinical staging is complete before treatment 	<ul style="list-style-type: none"> ▶ Compromised blood supply results in radioresistant hypoxic tumor cells ▶ Repopulation of tumor cells between surgery and starting radiation therapy ▶ Larger radiation field

TABLE 2 Timing of Chemotherapy Relative to Surgery⁴⁸

Timing	Advantages	Disadvantages
Preoperative	<ul style="list-style-type: none"> ▶ Reduction in tumor size facilitates surgical resection ▶ Allows determination of tumor sensitivity to chemotherapy, which helps determine prognosis and postoperative chemotherapy 	<ul style="list-style-type: none"> ▶ Delayed wound healing ▶ Risk of tumor growth resulting in more difficult and aggressive surgical resection
Intraoperative	<ul style="list-style-type: none"> ▶ Direct (intralesional or intratumoral) administration of chemotherapy into the tumor bed ▶ Increased tumor drug levels without increased systemic toxicity ▶ Treatment of microscopic metastatic disease 	Decreased wound healing
Postoperative	<ul style="list-style-type: none"> ▶ Chemotherapy is more effective when distant microscopic disease is present and cell turnover rate is higher at primary and metastatic sites ▶ Definitive surgery is not delayed ▶ Wound healing is not delayed 	<ul style="list-style-type: none"> ▶ Efficacy of chemotherapy is difficult to determine ▶ Decreased blood supply to tumor may decrease chemotherapy efficacy

residual microscopic tumor burden. Adjuvant radiation therapy is recommended for residual microscopic disease in surgical wounds (e.g., incompletely resected canine MCT or STS; feline VAS),⁴⁷ and adjuvant chemotherapy is recommended for tumors with a high metastatic risk and presumptive disseminated microscopic tumor burden (e.g., canine HSA, appendicular OSA, oral melanoma). Surgical resection of the tumor can facilitate adjunctive therapy by reducing the gross tumor burden, identifying tumor margins, and removing drug- and radiation-resistant cells, circulating immune complexes, and tumor-associated immunosuppressants.² For dogs with STS, adjuvant radiation therapy is much more effective against local micro-

scopic disease, with 1-year disease-free control rates of more than 95% for dogs with residual microscopic disease but only 50% for dogs with macroscopic tumor burden.^{15,17} However, adjuvant radiation therapy can increase the risk of wound complications, especially if started before 7 days postoperatively.^b The potential for complications increases as total radiation dose, dose per fraction, and radiation field size increase.² In general, however, postoperative radiation therapy is associated with fewer local wound complications than preoperative irradiation.^{20,48}

^bHenry CJ, Veterinary Cancer Society Meeting, 2003, personal communication.

For most cases, chemotherapy is administered in the adjunctive setting, usually starting at 10 to 14 days postoperatively, although start times of 0 to 21 days have been reported.⁴⁹ Chemotherapy can also have agent-specific local and systemic effects. Theoretically, alkylating agents, antimetabolites, antitumor antibiotics, and corticosteroids can have deleterious effects on wound healing. However, clinical data do not support these findings. Chemotherapy should be delayed until wound healing has begun (i.e., 7 to 10 days) and the risk of wound complications is low. This time frame allows wound fibroplasia and neovascularization to begin while maintaining a favorable environment for the antineoplastic effects of the chemotherapy agents, such as low tumor burden and few drug-resistant cells.³¹

Itations of minimally invasive surgery for the management of intracavitary tumors include the loss of tactile sensation, potential to miss metastatic lesions or underestimate surgical margins, decreased ability to adequately control unexpected hemorrhage, and need for a larger incision to remove the tumor following resection.⁵¹ There is also an increased risk of tumor seeding and local recurrence at portal sites as a result of forced extraction of tumors through an incision smaller than the tumor.^{50,51} To avoid this complication, tumors can be placed in a nylon specimen bag and morcellated, but this practice results in the loss of the ability to determine surgical margins.⁵¹ Another potential complication associated with laparoscopic surgery is that insufflation increases intraabdominal pressure, which has been shown to significantly increase proliferation of carcinoma cells and tumor cell adherence to matrix proteins.^{50,51} Hand-assisted laparoscopic and thoracoscopic surgery is becoming more popular in human medicine because it combines the advantages of minimally invasive surgery (especially visualization) and open surgery (tactile sensation, hemostasis, and tumor extraction).⁵¹

Second-Look Surgery

Second-look laparotomy, or repeat surgical exploration, has been reported in dogs with intraabdominal tumors.⁵² Second-look laparotomy (or laparoscopy) is aimed at assessing the degree of response to adjunctive therapies when noninvasive tests suggest a complete response; it is less commonly used for palliation of large or recurrent tumors.⁵² Second-look laparotomy for assessing therapy response is performed at the completion of adjunctive chemotherapy protocols, has a high sensitivity and specificity for detecting local tumor recurrence and metastasis, and provides valuable information on whether adjunctive treatments should be continued or modified.⁵² Disadvantages include the additional costs and potential complications associated with a second invasive surgical procedure. However, complications are uncommon and usually minor.⁵²

Palliative Surgery

The aim of palliative surgery is to alleviate clinical signs and improve the quality of life in animals with tumors when the type or extent

QuickNotes

Histopathologic analysis is essential for diagnosing tumor type, assessing margins for completeness of excision, and tumor grading (if appropriate). These findings determine postoperative management and the need for further treatment, such as radiation therapy and chemotherapy.

Other Types of Oncologic Surgery Preventive Surgery

The major role of surgery in the management of animals with cancer is definitive surgical resection, but surgery can also be used for the prevention and palliation of cancer. Examples of preventive surgery include prepubertal ovariectomy to significantly reduce or eliminate the risk of mammary, ovarian, and uterine tumors; castration to reduce the risk of Sertoli cell tumors in cryptorchid dogs and local recurrence of perianal adenomas; and removal of precancerous skin lesions in white cats to decrease the risk of dermal squamous cell carcinoma.

Laparoscopic and Thoracoscopic Surgery

Minimally invasive surgery is widely used for the diagnosis, staging, treatment, monitoring, and palliation of benign and intraabdominal and intrathoracic malignant diseases in people and has been reported in the management of primary and metastatic lung tumors in dogs.^{50,51} Laparoscopic surgery may be preferred for staging and resection of small benign tumors, while open surgery is recommended for large benign tumors and all malignant tumors.^{50,51} The advantages of minimally invasive surgery include the ability to thoroughly explore the affected body cavity with improved visualization under magnification, conduct regional staging, and remove the tumor through a smaller incision, resulting in less postoperative pain and better cosmetic results.⁵¹ The lim-

of disease prevents curative-intent surgical resection or other treatment.^{1,3} Palliative surgery should be carefully considered and only performed when the morbidity associated with the surgical procedure is outweighed by the potential benefits to the animal and owner.² Debulking surgery is rarely palliative. Examples of palliative surgery include splenec-

tomy for a dog with a ruptured splenic HSA, limb amputation for a dog with a pathologic fracture or unremitting pain secondary to a primary bone tumor, pulmonary metastasectomy for select dogs with hypertrophic osteopathy secondary to a metastatic lung lesion, and gastrojejunostomy for unresectable pyloric, duodenal, or pancreatic lesions.

References

1. Gilson SD, Stone EA. Principles of oncologic surgery. *Compend Contin Educ Pract Vet* 1990;12:827-838.
2. Withrow SJ. Surgical oncology. In: Withrow SJ, MacEwen EG, eds. *Small Animal Clinical Oncology*. 3rd ed. Philadelphia: Saunders; 2001:70-76.
3. Soderstrom MJ, Gilson SD. Principles of surgical oncology. *Vet Clin North Am Small Anim Pract* 1995;25:97-110.
4. Knight K, Wade S, Balducci L. Prevalence and outcomes of anemia in cancer: a systematic review of the literature. *Am J Med* 2004;116(suppl 7A):11S-26S.
5. Shander A, Knight K, Thurer R, et al. Prevalence and outcome of anemia in surgery: a systematic review of the literature. *Am J Med* 2004;116(suppl 7A):58S-69S.
6. Kerwin SC, Mauldin GE. Hemostasis, surgical bleeding, and transfusion. In: Slatter D, ed. *Textbook of Small Animal Surgery*. 3rd ed. Philadelphia: Saunders; 2003:44-65.
7. McGuire DB. Occurrence of cancer pain. *J Natl Cancer Inst Monogr* 2004;32:51-56.
8. Marks SL. The principles and practical application of enteral nutrition. *Vet Clin North Am Small Anim Pract* 1998;28:677-708.
9. Dunning D. Surgical wound infection and the use of antimicrobials. In: Slatter D, ed. *Textbook of Small Animal Surgery*. 3rd ed. Philadelphia: Saunders; 2003:113-122.
10. Dernel WS, Withrow SJ. Preoperative patient planning and margin evaluation. *Clin Tech Small Anim Pract* 1998;13:17-21.
11. Simpson AM, Ludwig LL, Newman SJ, et al. Evaluation of surgical margins required for complete excision of cutaneous mast cell tumors in dogs. *JAVMA* 2004;224:236-240.
12. Choo R, Woo T, Assaad D, et al. What is the microscopic tumor extent beyond clinically delineated gross tumor boundary in nonmelanoma skin cancers? *Int J Radiat Oncol Biol Phys* 2005;62:1096-1099.
13. Einstein R, Sorgente N, Soble LW, et al. The resistance of certain tissues to invasion. Penetrability of explanted tissues by vascularized mesenchyme. *Am J Pathol* 1973;73:765-774.
14. Fortner JG. Inadvertent spread of cancer at surgery. *J Surg Oncol* 1993;53:191-196.
15. Forrest LJ, Chun R, Adams WM, et al. Postoperative radiotherapy for canine soft tissue sarcoma. *J Vet Intern Med* 2000;14:578-582.
16. McKnight JA, Mauldin GN, McEntee MC, et al. Radiation treatment of incompletely resected soft-tissue sarcomas in dogs. *JAVMA* 2000;217:205-210.
17. McChesney SL, Withrow SJ, Gillette EL, et al. Radiotherapy of soft tissue sarcomas in dogs. *JAVMA* 1989;194:60-63.
18. Virkus WW, Marshall D, Enneking WF, et al. The effect of contaminated surgical margins revisited. *Clin Orthop Relat Res* 2002;397:89-94.
19. Wong CK, Lam YL, So YC, et al. Management of extremity soft tissue sarcoma after unplanned incomplete resection: experience of a regional musculoskeletal tumour center. *Hong Kong Med J* 2004;10:117-122.
20. Kharti VP, Goodnight JE. Extremity soft tissue sarcoma: controversial management issues. *Surg Oncol* 2005;14:1-9.
21. Manoso MW, Frassica DH, Deune EG, et al. Outcomes of re-excision after unplanned excisions of soft-tissue sarcomas. *J Surg Oncol* 2005;91:153-158.
22. Kuntz CA. Sarcoma surgery technique debated. *Vet Pract News* 2001;13:5.
23. Karakousis CP. Principles of surgical dissection. *J Surg Oncol* 1982;21:205-206.
24. Bacon NJ, Dernel WS, Ehrhart N, et al. Evaluation of primary re-excision after recent inadequate resection of soft tissue sarcomas in dogs: 41 cases (1999-2004). *JAVMA* 2007;230:548-554.
25. Noguera JJ, Jagelman DG. Principles of surgical resection. Influence of surgical technique on treatment outcome. Colorectal cancer. *Surg Clin North Am* 1993;73:103-116.
26. Turnbull RB, Kyle K, Watson FR, et al. Cancer of the colon: the influence of the no-touch isolation technique on survival rates. *Ann Surg* 1967;166:420-427.
27. Rizzo LB, Ritchey JW, Higbee RG, et al. Histologic comparison of skin biopsy specimens collected by use of carbon dioxide or 810-nm diode lasers from dogs. *JAVMA* 2004;225:1562-1566.
28. Mann FA, Pace LW. Marking margins of tumorectomies and excisional biopsies to facilitate histological assessment of excision completeness. *Semin Vet Med Surg (Small Anim)* 1993;8:279-283.
29. Sweitzer KL, Nathanson SD, Nelson LT, et al. Irrigation does not dislodge or destroy tumor cells adherent to the tumor bed. *J Surg Oncol* 1993;53:184-190.
30. Reinbach D, McGregor JR, O'Dwyer PJ. Effect of suture material on tumour cell adherence at sites of colonic injury. *Br J Surg* 1993;80:774-776.
31. Waldron DR, Zimmerman-Pope N. Superficial skin wounds. In: Slatter D, ed. *Textbook of Small Animal Surgery*. 3rd ed. Philadelphia: Saunders; 2003:259-273.
32. McEntee MC, Samii VF, Walsh P, et al. Postoperative assessment of surgical clip position in 16 dogs with cancer: a pilot study. *JAAHA* 2004;40:300-308.
33. Ribeiro U, Safatle-Ribeiro AV, Zilberstein B, et al. Does the intraoperative peritoneal lavage cytology add prognostic information in patients with potentially curative gastric resection? *J Gastrointest Surg* 2006;19:170-177.
34. Aper R, Smeak D. Complications and outcome after thoracodorsal axial pattern flap reconstruction of forelimb skin defects in 10 dogs, 1989-2001. *Vet Surg* 2003;32:378-384.
35. Aper RL, Smeak DD. Clinical evaluation of caudal superficial epigastric axial pattern flap reconstruction of skin defects in 10 dogs (1989-2001). *JAAHA* 2005;41:185-192.
36. Withrow SJ. Biopsy principles. In: Withrow SJ, MacEwen EG, eds. *Small Animal Clinical Oncology*. 3rd ed. Philadelphia: Saunders; 2001:63-69.
37. Powers BE. The pathology of neoplasia. In: Withrow SJ, MacEwen EG, eds. *Small Animal Clinical Oncology*. 3rd ed. Philadelphia: Saunders; 2001:4-17.
38. Newman SJ. Diagnostic pathology for the cancer patient. *Clin Tech Small Anim Pract* 2003;18:139-144.
39. Powers BE, Hoopes PJ, Ehrhart EJ. Tumor diagnosis, grading, and staging. *Semin Vet Med Surg (Small Anim)* 1995;10:158-167.
40. McArdle JP. Three-dimensional assessment of surgical excision margins in skin tumor resection biopsies. *Pathology* 1990;22:129-132.
41. Wick MR, Mills SE. Evaluation of surgical margins in anatomical pathology: technical, conceptual, and clinical considerations. *Semin Diagn Pathol* 2002;19:207-218.
42. Rochat M, Mann FA, Pace LW, et al. Identification of surgical biopsy borders by use of India ink. *JAVMA* 1992;201:873-878.
43. Seitz SE, Foley GL, Marretta SM. Evaluation of marking materials for cutaneous surgical margins. *Am J Vet Res* 1995;56:826-833.

44. Reimer SB, Séguin B, DeCock HE, et al. Evaluation of the effect of routine histologic processing on the size of skin samples obtained from dogs. *Am J Vet Res* 2005;66:500-505.
45. Mistry RC, Qureshi SS, Kumaran C. Post-resection mucosal shrinkage in oral cancer: quantification and significance. *J Surg Oncol* 2005;91:131-133.
46. Tanvetyanon T, Clark JI, Campbell SC, et al. Neoadjuvant therapy: an emerging concept in oncology. *South Med J* 2005;98:338-344.
47. McEntee MC. Principles of adjunct radiotherapy and chemotherapy. *Vet Clin North Am Small Anim Pract* 1995;25:133-148.
48. Séguin B, McDonald DE, Kent MS, et al. Tolerance of cutaneous or mucosal flaps placed into a radiation therapy field in dogs. *Vet Surg* 2005;34:214-222.
49. Berg J, Gebhardt MC, Rand WM. Effect of timing of postoperative chemotherapy on survival of dogs with osteosarcoma. *Cancer* 1997;79:1343-1350.
50. Ko AS, Lefor AT. Laparoscopic surgery. In: DeVita VT, Hellman S, Rosenberg SA, eds. *Cancer: Principles and Practice of Oncology*. 7th ed. Philadelphia: Lippincott Williams & Wilkins; 2005:253-266.
51. Ouellette JR, Ko AS, Lefor AT. The physiologic effects of laparoscopy: applications in oncology. *Cancer J* 2005;11:2-9.
52. Stancliff RM, Gilson SD. Use of cisplatin, 5-fluorouracil, and second-look laparotomy for the management of gastrointestinal adenocarcinoma in three dogs. *JAVMA* 2004;225:1412-1417.

3 CE
CREDITS

CE TEST

This article qualifies for 3 contact hours of continuing education credit from the Auburn University College of Veterinary Medicine. Subscribers may take individual CE tests online and get real-time scores at CompendiumVet.com. Those who wish to apply this credit to fulfill state relicensure requirements should consult their respective state authorities regarding the applicability of this program.

- Which surgical dose is appropriate for curative-intent resection of tumors?
 - marginal and wide resection
 - marginal and radical resection
 - wide and radical resection
 - debulking and wide resection
- During tumor excision, it is acceptable to
 - directly handle the tumor.
 - "shell out" well-encapsulated tumors.
 - use multifilament suture materials for ligation and wound closure.
 - manipulate the tumor with stay sutures or atraumatic surgical instruments.
- Histologic grading is important for determining prognosis for
 - canine MCTs.
 - feline MCTs.
 - canine brain and spinal cord meningiomas.
 - feline STSs.
- When is marginal resection of a tumor indicated?
 - never
 - always
 - for intestinal tumors
 - for distal-extremity tumors when surgery will be followed by radiation therapy
- The minimum surgical margin for wide resection of a grade II MCT is ____ cm.
 - 1
 - 2
 - 3
 - 4
- The minimum surgical margin for wide resection of an STS is ____ cm.
 - 1
 - 2
 - 3
 - 4
- Reconstructive surgery should be avoided during the initial surgical management of a tumor because it increases the
 - risk of local tumor recurrence.
 - extent of a tumor if surgical resection is incomplete.
 - risk of metastasis.
 - risk of infection.
- Which method of submitting a tumor sample to a laboratory is correct?
 - A segment of the tumor should be fixed in 10% formalin with a 1:10 ratio of tumor-to-formalin and submitted to a veterinary laboratory.
 - The tumor margins should be inked, and the tumor should be fixed in 10% formalin with a 1:5 ratio of tumor to formalin and submitted to a veterinary laboratory.
 - The tumor margins should be inked, and the tumor should be fixed in 10% formalin with a 1:10 ratio of tumor to formalin and submitted to a human laboratory.
 - The tumor margins should be inked, and the tumor should be fixed in 10% formalin with a 1:10 ratio of tumor to formalin and submitted to a veterinary laboratory.
- The intention of postoperative chemotherapy is to minimize the risk of
 - local tumor recurrence.
 - metastatic disease.
 - infection.
 - wound dehiscence.
- The intention of full-course postoperative radiation therapy is to minimize the risk of
 - local tumor recurrence.
 - metastatic disease.
 - infection.
 - wound dehiscence.