

Compendium

Feline Uveitis

Angelie K. Shukla, BSc, DVM

Chantale L. Pinard, DVM, MSc, DACVO

University of Guelph

Abstract: Uveitis is defined as inflammation of the vascular tunic of the eye, the uvea. Although inflammation can affect the entire uvea, clinical signs may present predominantly in either the anterior or the posterior chamber. Anterior uveitis lesions may affect the cornea, anterior chamber, iris, and lens, whereas posterior uveitis anomalies may be located in the vitreous and fundus. Uveal inflammation is often a sentinel finding indicative of underlying systemic pathology. Causes of feline uveitis are numerous, with infectious disease being the most common. Clinical signs are often nonspecific, and recurrence of disease is common, posing the challenges of accurate diagnosis and appropriate treatment.

Uveitis is a common form of feline ocular disease that may result in permanent blindness if not identified and treated properly and promptly¹⁻³ (BOX 1). Potential causes of uveitis in cats are numerous; ocular signs typically indicate an underlying systemic disease process. An underlying or associated systemic disease was linked to up to 70% of cases of feline uveitis in one report.⁴

Etiologies of feline uveitis can be broadly categorized into infectious, immune-mediated, neoplastic, traumatic, and idiopathic. Of identified causes, infectious disease is by far the most common.⁵ I (C. P.) have also found trauma to have a significant causal relationship compared with idiopathic and infectious causes when evaluating etiologic risk factors of feline uveitis compared with a control population. However, in as many as 62% to 70% of cases, no underlying cause is identified.^{4,6}

Ocular effects of uveitis can be severe and may have a number of devastating sequelae, such as iris bombé with secondary glaucoma, lens subluxation/luxation, cataract formation, and blindness.^{3,7,8} Uveitis has been reported to be the leading cause of feline glaucoma.⁹

Anatomy

The uvea is the vascular tunic of the eye. It is located deep to the sclera and sandwiched between the retina and sclera in the posterior segment of the eye (FIGURE 1). It is composed of three discrete parts: (1) the iris and (2) the ciliary body, making up the anterior

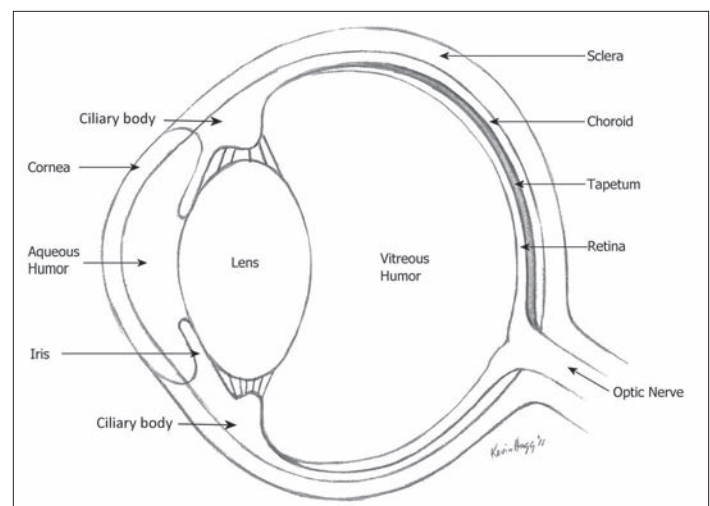


Figure 1. Anatomy of the eye. The uveal tract is composed of the iris and ciliary body in the anterior segment and of the choroid (between retina and sclera) in the posterior segment of the eye. The tapetum covers the inner aspect of the choroid in the dorsal aspect of the posterior segment of the eye.

Box 1. Types of Uveitis

- **Anterior uveitis** or **iritidocyclitis**: inflammation of the iris and ciliary body
- **Posterior uveitis** or **choroiditis**: inflammation of the choroid
- **Panuveitis**: inflammation of both anterior and posterior chambers of the eye

uvea, and (3) the choroid, making up the posterior uvea. The iris is composed of sphincter and dilator muscles that control the amount of light entering the eye. The ciliary body contains epithelial cells that produce aqueous humor (AH). It is also the site of the blood-aqueous barrier (BAB), which regulates the entry of molecules into the eye. The BAB is composed of an endothelial barrier and an epithelial barrier, which prevent proteins and inflammatory cells from entering the AH; this results in the protein concentration of the AH being much lower than that of plasma. The choroid, continuous with the ciliary body, provides a vascular supply to the retina, which is located on its inner surface. The reflective tapetum covers the choroid in the dorsal aspect of the globe.

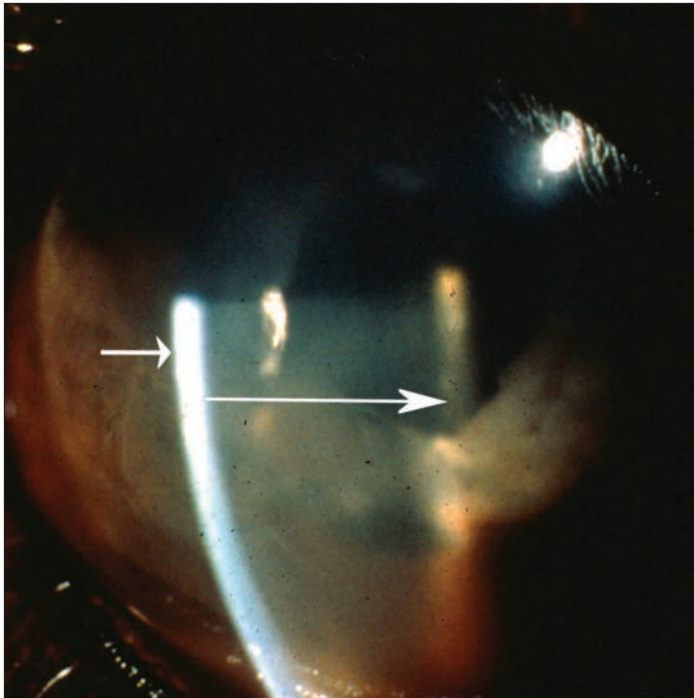


Figure 2. Aqueous flare. The beam of light starts at the cornea (*short arrow*) and the Tyndall effect (*long arrow*) is seen in the anterior chamber. *Courtesy of Dr. Dennis Brooks (DVM, PhD, DACVO), Professor, Comparative Ophthalmology, University of Florida*

Pathophysiology

Although inciting causes of uveitis are numerous, the sequence of events that occur as a result of insult to the uvea is similar regardless of etiology. Following uveal damage, the BAB is disrupted and prostaglandins and leukotrienes (which mediate vasodilation and increase vascular permeability) leak into the eye.¹⁰ The breakdown of the BAB also allows the entry of proteins, other inflammatory mediators (cytokines), and inflammatory cells into the eye.¹⁰ These events lead to the clinical signs associated with uveitis.

Clinical Signs

The clinical presentation of uveitis is variable and usually non-specific to etiology. The hallmark signs of ocular pain, namely blepharospasm, enophthalmos, photophobia, and epiphora, are common.^{1,7,11} Additionally, signs of anterior uveitis can include one or more of the following: conjunctival hyperemia (chronic or recurrent), corneal edema (perilimbal, focal, or diffuse), aqueous flare (inflammatory cells and/or protein deposits in suspension within the anterior chamber; **FIGURE 2**), hyphema (**FIGURE 3**), hypopyon, keratic precipitates (inflammatory cells and/or protein deposits on the inner aspect of the corneal endothelium), miosis (caused by prostaglandin release), iris thickening (iritis), iris color change (in chronic cases, due to proliferation of melanocytes), and posterior synechiae (adherence of pupillary margin to anterior lens capsule).^{1,7,11,12} Aqueous flare and keratic precipitates can be challenging to detect even for experienced practitioners; although direct ophthalmoscopy can be used, slit lamp biomicroscopy has

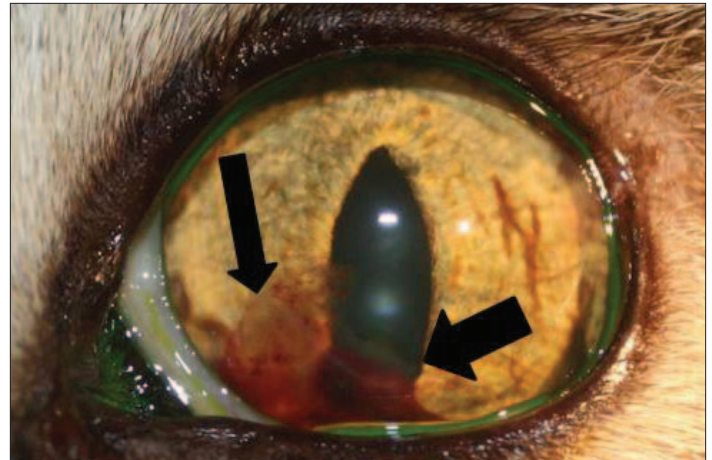


Figure 3. Anterior uveitis. Hyphema (*thick arrow*) and a fibrin clot (*narrow arrow*) are seen in the anterior chamber of this left eye.

superior optics to visualize these lesions.

Low intraocular pressure (IOP) is a common feature of uveitis. An IOP <10 mm Hg or a difference in IOP of 10 mm Hg between the affected eye and the normal eye is suggestive of uveitis. A low IOP is expected because inflammation of the ciliary body results in decreased AH production¹³ as well as an increase in AH outflow through the uveoscleral route in response to prostaglandins.¹⁴ However, the reliability of finding a low IOP depends on the

presence of concurrent secondary ocular pathologies, specifically glaucoma.³ Glaucoma can be caused by buildup of inflammatory debris and cells in the iridocorneal angle, leading to impaired AH flow within the eye, or by mechanical disruption of AH flow through the pupil from development of posterior synechiae.^{2,3}

Signs of posterior uveitis include cellular infiltrate in the vitreal body (vitritis), chorioretinal inflammation (focal or generalized hemorrhage, exudate or transudate leading to retinal detachment, subretinal granulomas; **FIGURE 4**), and, in severe cases, blindness.^{2,12}

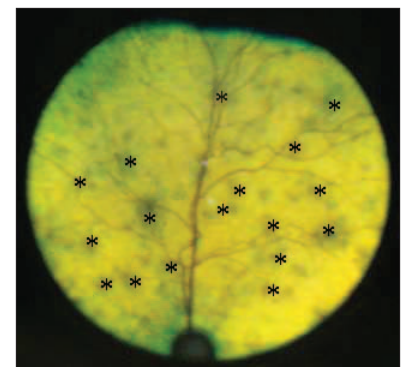


Figure 4. Posterior uveitis. Active chorioretinitis lesions (*stars*) of unknown etiology; this patient responded to treatment with doxycycline. *Courtesy of Dr. Ellison Bentley (DVM, DACVO) Clinical Associate Professor, Comparative Ophthalmology, University of Wisconsin-Madison*

Diagnostic Tests

A minimum ophthalmic database includes the following:

- A thorough history
- A neuro-ophthalmic examination that assesses the following:
 - Dazzle reflex*: A bright light is shone into each eye; the normal response is a blink

- Menace response*: An abrupt gesture is made toward each eye; the normal response is a blink
- Pupillary light reflexes*: A bright light is shone into each eye; the normal response is for the illuminated pupil to constrict (direct reflex) and the contralateral pupil to constrict equally (indirect reflex)
- Palpebral reflexes*: The medial and lateral canthus of the eye are touched; the normal response is a blink
- A Schirmer tear test
- Fluorescein staining
- Tonometry
- Examination of all ocular structures with direct and indirect ophthalmoscopy

As long as the IOP is <25 mm Hg, dilation of the pupil with 1% tropicamide is recommended to best visualize the fundus. If the IOP is \geq 25 mm Hg, dilation of the pupil is not recommended, as mydriasis may cause glaucoma due to compression of the iridocorneal angle. In most cases, it is advisable to build a minimum systemic database consisting of a comprehensive physical examination, a complete blood count (CBC), a serum biochemistry panel, and urinalysis.^{3,7} More advanced and specific testing is recommended depending on the suspected underlying etiology, including serologic titer measurement (on blood, aqueous, or vitreal samples), thoracic radiography, and abdominal ultrasonography (**TABLE 1**).

Etiology

Specific etiologies of feline uveitis are numerous and may be broadly categorized into endogenous (immune mediated or neoplastic), exogenous (infectious or traumatic), and idiopathic.

Infectious Causes

Feline Immunodeficiency Virus

FIV, a retrovirus, exists endemically in all domestic feline populations. The disease is typically contracted via bite wounds; therefore, outdoor male cats are more likely to become infected. Infected individuals may never develop disease or may not develop it until 4 to 6 years of age or older. Viral damage commonly causes concurrent conjunctivitis and anterior uveitis. Other ocular signs may include chorioretinitis secondary to another infectious agent, glaucoma, lens luxation, and pars planitis (inflammation at the junction of the ciliary body and retina).¹⁵ The prognosis varies depending on stage and expression of immunodeficiency. All positive FIV ELISA results should be confirmed using a more specific test (e.g., Western blot, immunofluorescent antibody [IFA], virus isolation [VI]). Cats should not be euthanized based on a positive test result, as individuals may remain asymptomatic for years after diagnosis.

Euthanasia is not recommended for cats with clinical signs of FIV if the signs can be medically managed and pain control established. However, if severe uveitis with glaucoma is unresponsive to medication, enucleation should be performed. Clients should be aware that FIV-positive cats are more likely to develop infections and may be prone to immune-mediated diseases and neoplasia.¹⁶

Feline Leukemia Virus

Feline leukemia virus (FeLV), another retrovirus, may infect cats through mutual grooming and sharing of water or food bowls, but it is most often transmitted via saliva into bite wounds.^{17,18} Recent research suggests that unvaccinated cats exposed to the virus remain infected for life^{19,20}; previously, it was believed that up to two-thirds of individuals were eventually able to clear the infection. Cats may be able to revert to an aviremic state (also termed *regressive infection*) in which no antigen is detectable in blood, but FeLV proviral DNA may still be detected by a polymerase chain reaction (PCR) assay. Alternatively, cats may develop progressive infection due to an insufficient immune response to the virus. These cats are expected to develop clinical disease, with systemic effects expected to be fatal within a few years.¹⁸ Hence, clinical signs become apparent at a younger age than in cats infected with FIV. The manifestation of this disease includes uveitis.^{17,21} Ophthalmic findings can include uveal lymphoma, iridocyclitis, hypopyon, keratic precipitates, and chorioretinitis.^{7,10} Most persistently viremic cats develop systemic signs of disease, with 70% to 90% of individuals surviving between 1.5 and 3 years after the development of clinical signs.²¹ Similar to FIV, cats should not be euthanized based on a positive test result, as individuals may remain asymptomatic for years after diagnosis; all positive ELISA results should be confirmed using a more specific test (IFA, VI). Clients should be aware that FeLV-positive cats are more likely to develop infections and may be prone to immune-mediated diseases and neoplasia.

Feline Infectious Peritonitis

FIP is an immune-mediated disease that may affect any felid infected with feline coronavirus.^{17,22} Purebred cats are proposed to be at increased risk for FIP.^{22,23} Approximately 5% to 13% of seropositive cats develop clinical signs of FIP; cats less than 1 year of age are at the highest risk.²² Manifestation of FIP may be effusive (wet) or non-effusive (dry). The dry form is more commonly associated with intraocular disease.²⁴ Ocular manifestations of the disease include panuveitis with fibrin deposition in the anterior chamber, granulomatous chorioretinitis, retinal vasculitis (perivascular infiltration of white blood cells), retinal detachment, and optic neuritis.^{7,12,22} The prognosis is grave, as the disease is invariably fatal. More recently, a study involving three cats examined the effects of polyprenyl immunostimulant as a new therapy in the treatment of

Key Points

- Uveitis is a common feline ocular disease that may result in blindness if not identified and properly treated.
- The causes of feline uveitis are numerous, and specific diagnostic tests may be required to arrive at a diagnosis.
- Aggressive symptomatic and, when appropriate, specific therapy is necessary to decrease pain and inflammation and to preserve vision.
- The prognosis varies depending on the underlying etiology. If no causative agent is identified, clients should be advised that recurrence of uveitis is possible.



Table 1. Agent-Specific Diagnostic Tests for Feline Uveitis

Agent	Whole Blood	Serology	Other	Comment
FIV	PCR, VI	ELISA (antibody), Western blot, immunochromatography	PCR (tissue, AH) ^a	<ul style="list-style-type: none"> • Serology is superior to PCR (sensitivity/specificity of PCR varies depending on lab used) • VI rarely used • Western blot is gold standard
FeLV	PCR, VI	ELISA (antigen), immunochromatography	IFA, PCR (RNA [saliva, feces])	<ul style="list-style-type: none"> • Cats with regressive infection may test negative on IFA • Cats with conflicting results (i.e., negative IFA, positive p27 antigen detection) should be retested 60 days later with p27 antigen detection • VI rarely used
FIP	PCR	IFA	Histology of affected tissues	<ul style="list-style-type: none"> • Histology is superior • Tests do not distinguish between FIP and FCoV
FHV-1	VI	ELISA, Western blot	PCR (AH) ^a	<ul style="list-style-type: none"> • Superficial corneal ulcers supportive of diagnosis • VI is gold standard but rarely used • Western blot not commonly used
<i>Bartonella henselae</i>	Culture	Antibody titers, blood and serum culture using BAPGM	PCR (AH) ^a	<ul style="list-style-type: none"> • Diagnosis of exclusion; titers reflect exposure and are not specific for active infection • Blood contamination can skew PCR results • BAPGM is promising
<i>Toxoplasma gondii</i>	N/A	Positive IgM titer supportive, or 4× increase in serum IgG titers taken 2–4 wk apart	Histology of globe, fecal flotation (sugar or zinc sulfate centrifugation)	Negative fecal result does not rule out disease (only 1% of cats shed eggs)
Fungal diseases	N/A	<ul style="list-style-type: none"> • Blastomycosis: ELISA, AGID • Coccidioidomycosis: ELISA, AGID, CF, latex agglutination • <i>Cryptococcus</i>: ELISA latex agglutination • Histoplasmosis: AGID, CF (not reliable for this agent) 	Histology of globe, cytology, culture of vitreous	Evaluate potential for systemic involvement
Neoplasia	N/A	N/A	Histology, cytology	Metastatic staging is recommended

AGID = agar gel immunodiffusion; AH = aqueous humor; BAPGM = *Bartonella* alpha Proteobacteria growth medium; CF = complement fixation; ELISA = enzyme-linked immunosorbent assay; FCoV = feline coronavirus; FeLV = feline leukemia virus; FHV-1 = feline herpesvirus 1; IFA = immunofluorescent antibody; N/A = not applicable; PCR = polymerase chain reaction; VI = virus isolation.

^aAH samples should be collected from patients under general anesthesia, using a 27- to 30-gauge needle inserted at the lateral limbus, 2 to 3 mm into the anterior chamber.

noneffusive FIP²⁵; although the results were promising, additional studies are needed to assess efficacy. Postmortem analysis should be performed on cats with suspected FIP that are euthanized; confirmation of the disease should be discussed with the owner along with preventive measures to limit exposure to other cats.

Feline Herpesvirus

Ocular disease is a common manifestation of feline herpesvirus (FHV-1) infection, with the virus inducing conjunctivitis and dendritic or superficial geographical corneal ulcers via cytopathic effects on conjunctival and corneal epithelial cells.¹⁷ Corneal

ulcerative keratitis may induce a “reflex uveitis” through stimulation of the trigeminal nerve. More recently, it has been postulated that endogenous FHV-1 is also a causative pathogen of uveitis.^{17,26} Transient uveitis was detected after experimental inoculation of specific-pathogen-free kittens with FHV-1. Feline herpesvirus DNA has also been isolated from AH in cats with uveitis when no other agent was identified.²⁶ The prognosis is variable because latency of the virus is common and infected cats may experience recurrence of clinical signs, typically induced by stress.²⁷

Bartonella henselae

A gram-negative bacterium, *Bartonella henselae* is known to commonly infect cats and humans; it causes chronic uveitis in both species, and the cat is considered the organism’s main host.²⁸ The bacterium replicates in endothelial cells and survives within erythrocytes.²⁸ Depending on geographic location, up to 93% of cats may have been exposed to the organism; therefore, a diagnosis of *Bartonella*-induced uveitis is suggested (not confirmed) by exclusion of other causes along with serologic findings, including response to appropriate therapy.^{28,29} The usefulness of serum and AH antibody testing for *Bartonella* spp is limited because antibodies can be detected in healthy cats as well as in cats with uveitis.²⁸ Recent work suggests that diagnosis requires confirmation using (1) enriched blood culture followed by PCR and (2) DNA sequencing involving PCR detection of *Bartonella* spp DNA in addition to enrichment culture of blood and serum samples in *Bartonella* alpha Proteobacteria growth medium.³⁰ Uveitis may be chronic due to the propensity of *B. henselae* to survive intracellularly for several years.^{28,31}

Fungal Disease

Histoplasma capsulatum, *Cryptococcus neoformans*, and, less commonly, *Coccidioides immitis* and *Blastomyces dermatitidis* are systemic fungal agents that have been associated with ocular disease in cats.^{37,32–35} Typical ocular presentations include granulomatous foci appearing clinically as keratic precipitates, highly cellular hypopyon, retinal granulomas, and retinal detachment. A recent report involving three cases of feline coccidiomycosis indicates that enophthalmos, conjunctival hyperemia, chemosis, and corneal neovascularization may also be observed.³⁶ Treatment with antifungal therapy should continue for 1 month beyond the resolution of clinical signs regardless of cost concerns. For example, in the three cases mentioned above, long-term therapy was continued in all patients, resulting in administration of fluconazole for more than 12 months in one cat.³⁶ The disease may manifest as a focal lesion; however, the disease is typically disseminated by the time lesions are detected.³⁷ The prognosis varies depending on the extent of tissues involved, owner finances, and time commitment.

Parasitic Causes

Toxoplasma gondii

Toxoplasma gondii is a common zoonotic intracellular parasite for which cats are the only definitive hosts. Infected cats shed oocysts in their feces; the oocysts become infective after exposure to the

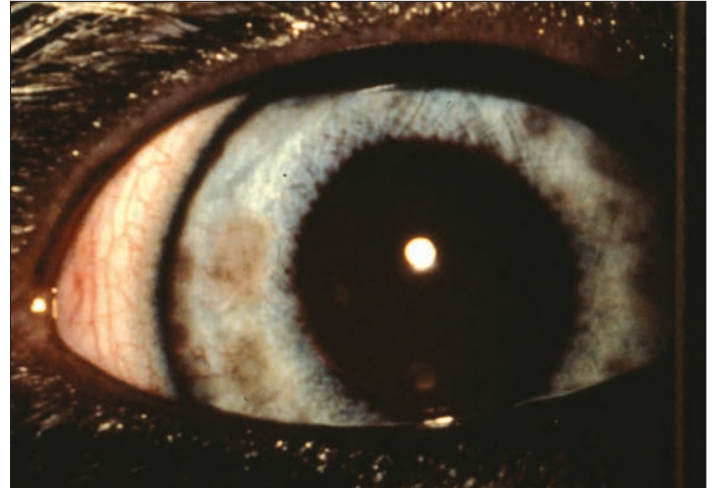


Figure 5. Iris nodules due to *Toxoplasma* infection. These nodules are within the anterior iridal stroma. Courtesy of Dr. Brooks

environment.³⁸ The estimated prevalence of toxoplasmosis in the cat population worldwide is 30% to 40%.³⁸ Clinical signs of disease include anterior and posterior uveitis.³⁹ The classic findings in *Toxoplasma*-induced uveitis include grey iridal nodules (**FIGURE 5**), multifocal dark grey lesions in the tapetal fundus, and fluffy white infiltrates in the nontapetal fundus.³⁹ Treatment of toxoplasmosis can be challenging because current therapies suppress replication of the tachyzoites; therefore, complete elimination of the organism is unlikely.⁴⁰

Other Parasites

Rarely, uveitis may be the result of aberrant parasite migration of *Cuterebra* and *Toxocara* larvae.^{3,41} *Cuterebra* larvae or track lesions of *Cuterebra* and *Toxocara* organisms may be visualized on fundic examination; histology reveals parasitic track lesions and/or coagulation necrosis and hemorrhage in affected areas such as the optic nerve head.⁴¹ Patients affected by ocular larval migrans may also present with neurologic signs, including behavioral changes, depression, and blindness due to migration of the parasite through the central nervous system.⁴¹

Immune-Mediated Causes

Although immune-mediated cases of feline uveitis are numerous, often making the search for an etiology difficult, a diagnostic workup is still recommended. Well-recognized forms of immune-mediated uveitis include phacolytic uveitis (chronic form of lens-induced uveitis) and phacoclastic uveitis (acute form of lens-induced uveitis). In phacolytic uveitis, cataractous lens proteins slowly leak across an intact lens capsule. In phacoclastic uveitis, the lens capsule ruptures (e.g., after perforating trauma), allowing a large amount of protein to leak rapidly from the lens. Phacoclastic uveitis may ultimately result in posttraumatic intraocular sarcoma.⁴² The prevalence of cataracts in the feline population is low; therefore, concurrent uveitis should be suspected when cataracts are observed.^{3,7}

Neoplastic Causes

Diffuse iridal melanoma is the most common neoplastic cause of feline uveitis.^{3,43} This tumor appears as a flat, brown-black, freckle-like lesion within the iris (FIGURE 6). It is important to note that not all freckle-like lesions are melanomas: iris melanosis and uveal cysts remain important diagnostic differentials. Differentiation between iris melanoma and melanosis can be challenging. Without definitive confirmation via an iridal biopsy, the velvety appearance of the hyperpigmented lesion, the coalescing nature of the lesions over time, and a unilateral presentation of areas of iris hyperpigmentation (iris melanosis) can be suggestive of iris melanoma. Invasion of the sclera and iridocorneal angle with resulting glaucoma is highly indicative of iris melanoma. Frequent reevaluation (i.e., every 3 to 4 months) to track these lesions by taking photos is a reasonable initial approach unless malignancy is suspected early on. The metastatic rate of this malignancy may be as high as 63%; therefore, enucleation of the affected eye is typically recommended, especially in cases with glaucoma or scleral invasion.⁴³ A highly effective treatment for canine uveal melanoma is diode laser ablation; however, this therapy has not yet been shown to be efficacious in feline patients.

Ocular sarcomas, which are typically associated with trauma,⁴² are also primary ocular tumors that may have epithelial or mesenchymal features. Although their origin is difficult to elucidate, it has been suggested that they may arise from lens epithelium.⁴² As metastasis of this tumor is expected, early enucleation of the affected eye is recommended.⁴³

The most common secondary neoplasm affecting the eye is lymphoma,⁴³ which also typically causes unilateral uveitis.

Trauma

Perforating or blunt trauma is a common cause of uveitis. Uveitis may also manifest secondary to ocular surgical procedures (i.e., corneal surgery, cataract surgery) and corneal ulceration. While

blunt trauma is less common than perforating trauma, it typically results in more damage to the globe. Ocular ultrasonography may be a useful adjunctive diagnostic tool, especially if the anterior chamber cannot be visualized. Treatment of trauma-induced uveitis follows the same general principles of symptomatic therapy for uveitis; however, the effects of trauma to other ocular structures must be considered. Corneal injury subsequent to trauma is common, making topical steroids an inappropriate choice for

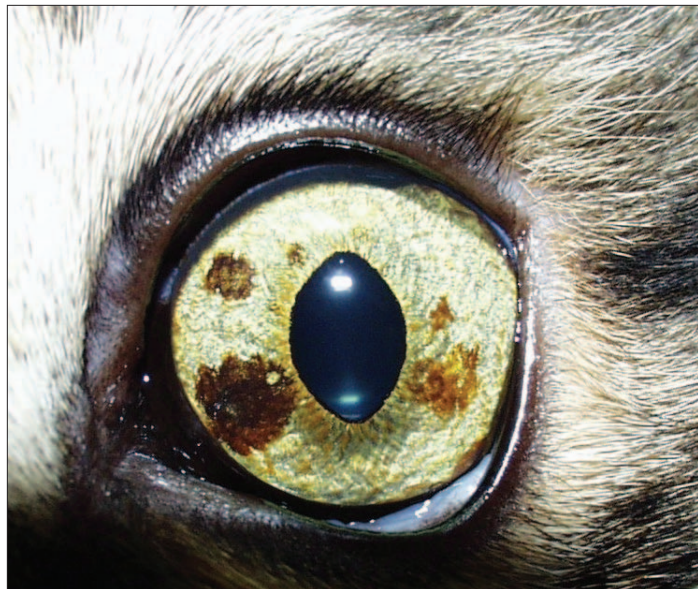

Figure 6. Diffuse iridal melanoma or melanosis. The dark freckles were confirmed to be melanoma on biopsy.

therapy. Topical and systemic NSAIDs are occasionally used in lieu of steroids in patients with endocrinopathies (e.g., diabetes mellitus), lymphosarcoma, or systemic infectious diseases⁴⁴; however, the risk of precipitating the progression of an existing corneal ulcer is not eliminated by using topical NSAIDs. Examples of commercially available topical NSAID ophthalmic solutions include diclofenac and flurbiprofen. Topical antibiotics are also indicated when corneal injury exists. The prognosis for vision and viability of the eye depends on the nature and extent of the trauma; if significant intraocular hemorrhage exists, the prognosis is guarded at best.

Idiopathic Uveitis

Reportedly, in as many as 70% of feline uveitis cases, no underlying etiology is identified.⁶ A complete diagnostic database is nevertheless recommended to allow for prompt and specific therapy if a specific underlying systemic disease can be found.¹² In cases of idiopathic uveitis, aggressive symptomatic treatment is recommended and the prognosis may be guarded, as recurrence is common.⁴⁴

Symptomatic Treatment of Feline Uveitis

Regardless of cause, the goals of treatment are to stabilize the BAB, decrease inflammation, treat ocular pain, minimize potential ocular sequelae, and preserve vision. When miosis is observed, administration of a mydriatic (atropine, tropicamide) is indicated to help prevent development of posterior synechiae, as well as to provide analgesia via cycloplegia (paralysis of the ciliary muscle). Dilation of the pupil should be maintained until clinical improvement of uveitis is observed; this may entail one to three times daily administration if the pupil is persistently miotic to administration every other day (or third day) if the dilated pupil relapses into miosis. Atropine accumulates in the eye and can have a long

Clinical Pearls

- To help rule in/out causes of feline uveitis, the ocular examination should include a neuro-ophthalmic examination, fluorescein staining, and tonometry.
- Uveitis is the most common cause of glaucoma in cats.
- Long-term therapy may be required in cases of uveitis caused by FIV or intraocular neoplasia and in cases of idiopathic uveitis.
- Chronic or recurrent conjunctivitis is often caused by underlying uveitis in cats.

Table 2. Summary of Topical and Systemic Agents Used in Feline Uveitis

Agent	Effect	Dose
Topical atropine 1%	<ul style="list-style-type: none"> • Mydriasis, cycloplegia • Max effect in 1 h • Duration of action: >60 h if administered repeatedly 	Administer q6–12h initially, then q12–72h to maintain dilation of pupil
Topical tropicamide 1%	<ul style="list-style-type: none"> • Mydriasis, cycloplegia • Max effect in 15 min • Duration of action: 8–9 h 	Administer q6–12h to maintain dilation
Topical prednisolone acetate 1% or topical dexamethasone 0.1% ^a	Antiinflammatory	Administer q1–12h depending on severity of case
Topical NSAIDs ^a	Antiinflammatory	Administer q6–12h depending on severity of case
Systemic prednisolone ^a	<ul style="list-style-type: none"> • Antiinflammatory • Indicated especially with choroiditis 	1–2 mg/kg/d divided into two doses, tapered as uveitis resolves
Systemic NSAIDs ^b	<ul style="list-style-type: none"> • Antiinflammatory • Useful when corticosteroids are contraindicated 	Meloxicam 0.1 mg/kg PO once; thereafter 0.05 mg/kg PO q24h (extralabel use)

^aContraindicated when corneal ulceration/trauma is present.

^bOnly one example is provided here.

duration of action (e.g., the pupil may remain dilated for several days to weeks after the last dose of atropine). Prolonged pupillary dilation is not of concern as long as the IOP remains below 25 mm Hg. Clients should be informed that cats may salivate after administration of atropine because of its bitter taste. Tropicamide can also be used but requires frequent administration

(e.g., every 6 to 8 hours) because its duration is not as long as that of atropine.

The inflammatory nature of uveitis dictates the use of topical and systemic antiinflammatory pharmaceuticals when corneal trauma is not present. Topical corticosteroids are recommended to suppress inflammation and help decrease protein leakage and deposition. Depending on the degree of inflammation, topical corticosteroids may initially be administered as frequently as once every hour until clinical improvement is observed. Systemic corticosteroids are reserved for posterior uveitis or severe anterior uveitis. Systemic NSAIDs are also recommended in the treatment of uveitis, particularly when the posterior uvea is involved and systemic corticosteroids are contraindicated. Standard treatment options are summarized in **TABLE 2**. The choice of medication and frequency of administration depend on the severity of the case. For example, mild anterior uveitis may require only once-daily administration of a topical steroid or twice-daily administration of a topical NSAID and may resolve within 1 or 2 weeks of therapy; however, severe posterior uveitis requires systemic administration of steroids, possibly for an extended period of time (weeks). Additional therapeutic options for specific causes of feline uveitis are summarized in **TABLE 3**.

Conclusions

Uveitis can be challenging to diagnose and treat in feline patients. Identifying the underlying cause allows better tailoring of therapy to alleviate patient discomfort, avoid or minimize sequelae, and, ultimately, improve prognosis for the patient. Recent advances in diagnostic tests and therapies allow for improved outcomes in feline uveitis.

Table 3. Examples of Systemic Therapy for Specific Etiologic Agents of Feline Uveitis^a

Agent	Systemic Therapy
FIV	Supportive care, AZT, AMD3100 (bicyclam), feline interferon- ω^b
FeLV	Supportive care, AZT, feline interferon- ω , ^b human recombinant α interferon, chemotherapy in some cases
FIP	Supportive care, systemic glucocorticoids, cyclophosphamide, polyprenyl immunostimulant
FHV-1	Supportive care, lysine, interferon
<i>Bartonella henselae</i>	Doxycycline
<i>Toxoplasma gondii</i>	Clindamycin hydrochloride
Fungal agents	Fluconazole, itraconazole
Neoplasia	Enucleation

AZT = 3'-azido-2',3'-dideoxythymidine.

^aTherapeutic agents listed should be used at appropriate dosages as listed in drug inserts/resources when appropriate. This is not an exhaustive list.

^bDomenech A, Miro G, Collado VM, et al. Use of recombinant interferon omega in feline retrovirois: from theory to practice. *Vet Immunol Immunopathol* 2011;143(3-4):301-306.

Acknowledgments

The authors thank Dr. Ellison Bentley (University of Wisconsin-Madison), Dr. Dennis Brooks (University of Florida), Kevin Hogg (University of Guelph), and Peter Jaspers-Fayer (University of Guelph) for their assistance with the figures and images in this article.

References

- Mandell DC, Holt E. Ophthalmic emergencies. *Vet Clin North Am Small Anim* 2005;35:455-480.
- Powell CC, Lappin MR. Causes of feline uveitis. *Compend Contin Educ Pract Vet* 2001; 23(2):128-141.
- Powell CC, Lappin MR. Diagnosis and treatment of feline uveitis. *Compend Contin Educ Pract Vet* 2001;23(3):258-266.
- Chavkin M, Lappin M, Powell, et al. Seroepidemiologic and clinical observation of 93 cases of uveitis in cats. *Prog Vet Comp Ophthalmol* 1992;2:29-36.
- Lappin MR. Feline infectious uveitis. *J Feline Med Surg* 2000;2:159-163.
- Davidson MG, Nasisse MP, English RV, et al. Feline anterior uveitis: a study of 53 cases. *J Am Anim Hosp Assoc* 1991;22:77-83.
- Colitz CMH. Feline uveitis: diagnosis and treatment. *Clin Tech Small Anim Pract* 2005;20:117-120.
- Olivero DK, Riis RD, Dutton AG, et al. Feline lens displacement: a retrospective analysis of 345 cases. *Prog Vet Comp Ophthalmol* 1991;194:239-244.
- Wilcock BP, Peiffer RL, Davidson MG. The causes of glaucoma in cats. *Vet Pathol* 1990;27:35-40.
- Rankin AJ, Krohn SG, Glickman NW, et al. Laser flaremetric evaluation of experimentally induced blood-aqueous barrier disruption in cats. *Am J Vet Res* 2002;63(5):750-756.
- Hakanson N, Forrester SD. Uveitis in the dog and cat. *Vet Clin North Am Small Anim Pract* 1990;20(3):715-735.
- Townsend WM. Canine and feline uveitis. *Vet Clin North Am Small Anim Pract* 2008; 38:323-346.
- Toris C, Pederson J. Aqueous humor dynamics in experimental iridocyclitis. *Invest Ophthalmol Vis Sci* 1987;28(3):477-481.
- Stern F, Bito L. Comparison of the hypotensive and other ocular effects of prostaglandins E2 and F2a on cat and rhesus monkey eyes. *Invest Ophthalmol Vis Sci* 1982; 22(5):588-598.
- English RV, Davidson MG, Nasisse MP, et al. Intraocular disease associated with feline immunodeficiency virus infection in cats. *J Am Vet Med Assoc* 1990;196(7):1116-1119.
- Hosie MJ, Addie D, Belak S, et al. Feline immunodeficiency. ABCD guidelines on prevention and management. *J Feline Med Surg* 2009;11:575-584.
- La Croix NC. Ocular manifestations of systemic disease in cats. *Clin Tech Small Anim Pract* 2004;20:121-128.
- Levy J, Crawford C, Hartmann K, et al. 2008 American Association of Feline Practitioners' Feline Retrovirus Management Guidelines. *J Feline Med Surg* 2008;10:300-316.
- Pepin AC, Tandon R, Cattori V, et al. Cellular segregation of feline leukemia provirus and viral RNA in leukocyte subsets of long-term experimentally infected cats. *Virus Res* 2007;127:9-16.
- Torres AN, Mathiason CK, Hoover EA. Re-examination of feline leukemia virus: host relationships using real-time PCR. *Virology* 2005;332:272-283.
- Lutz H, Addie D, Belak S, et al. Feline leukemia. ABCD guidelines on prevention and management. *J Feline Med Surg* 2009;11:565-574.
- Benetka V, Kubber-Heiss A, Kolodziejek J, et al. Prevalence of feline coronavirus types I and II in cats with histopathologically verified feline infectious peritonitis. *Vet Microbiol* 2004;99:31-42.
- Pesteanu-Somogyi LD, Radzai C, Pressler BM. Prevalence of feline infectious peritonitis in specific cat breeds. *J Feline Med Surg* 2006;8(1):1-5.
- Pedersen NC. An overview of feline enteric coronavirus and infectious peritonitis virus infections. *Feline Pract* 1997;23:7-20.
- Legendre AM, Bartges JW. Effect of polyprenyl immunostimulant on the survival times of three cats with the dry form of feline infectious peritonitis. *J Feline Med Surg* 2009;11(8):624-626.
- Maggs DJ, Lappin MR, Nasisse MP. Detection of feline herpesvirus-specific antibodies and DNA in aqueous humor from cats with or without uveitis. *Am J Vet Res* 1999;60:932-936.
- Maggs DJ. Update on pathogenesis, diagnosis and treatment of feline herpesvirus type 1. *Clin Tech Small Anim Pract* 2005;20(2):94-101.
- Fontenelle JP, Powell CC, Hill AE, et al. Prevalence of serum antibodies against *Bartonella* species in the serum of cats with or without uveitis. *J Feline Med Surg* 2008;10:41-46.
- Lappin MR, Kordick DL, Breitschwerdt EB. *Bartonella* spp antibodies and DNA in aqueous humour of cats. *J Feline Med Surg* 2000;2:61-68.
- Maggi RG, Duncan AW, Breitschwerdt EB. Novel chemically modified liquid medium that will support the growth of seven *Bartonella* species. *J Clin Microbiol* 2005;43(6): 2651-2655.
- Quimby JM, Elston T, Hawley J, et al. Evaluation of the association of *Bartonella* species, feline herpesvirus 1, feline calicivirus, feline leukemia virus and feline immunodeficiency virus with chronic feline gingivostomatitis. *J Feline Med Surg* 2008;10:66-72.
- Wilkinson G. Feline cryptococcosis: a review and seven case reports. *J Small Anim Pract* 1979;20:749-768.
- Gwin RM, Makley TA Jr, Wyman M, et al. Multifocal ocular histoplasmosis in a dog and cat. *J Am Vet Med Assoc* 1980;176(7):638-642.
- Nasisse MP, van Ed RT, Wright B. Ocular changes in a cat with disseminated blastomycosis. *J Am Vet Med Assoc* 1985;187(6):629-631.
- Greene RT, Troy CG. Coccidioidomycosis in 48 cats: a retrospective study (1984-1993). *J Vet Intern Med* 1995;9(2):86-91.
- Tofflemire K, Betbeze C. Three cases of feline ocular coccidioidomycosis: presentation, clinical features, diagnosis and treatment. *Vet Ophthalmol* 2010;13(3):166-172.
- Pearce J, Giuliano EA, Galle LE, et al. Management of bilateral uveitis in a *Toxoplasma gondii*-seropositive cat with histopathologic evidence of fungal panuveitis. *Vet Ophthalmol* 2007;10(4):216-221.
- Hughes SM, Hill F. Feline ocular toxoplasmosis: a case study and literature review. *Aust Vet Pract* 2008;38(1):2-8.
- Davidson MG. Toxoplasmosis. *Vet Clin North Am Small Anim Pract* 2000;30(5):1051-1062.
- Elmore SA, Jones JL, Conrad PA, et al. *Toxoplasma gondii*: epidemiology, feline clinical aspects, and prevention. *Trends Parasitol* 2010;26(4):190-196.
- Wyman M, Starkey R, Weisbrode S, et al. Ophthalmomyiasis (interna posterior) of the posterior segment and central nervous system myiasis: *Cuterebra* spp. in a cat. *Vet Ophthalmol* 2005;8(2):77-80.
- Zeiss CJ, Johnson EM, Dubielzig RR. Feline intraocular tumors may arise from transformation of lens epithelium. *Vet Pathol* 2003;40:355-362.
- Miller PE. Uvea. In: *Slatter's Fundamentals of Ophthalmology*. St. Louis, MO: Saunders Elsevier; 2008:203-229.
- Maggs D. Feline uveitis an "intraocular lymphadenopathy." *J Feline Med Surg* 2009; 11:167-182.



3 CE Credits

This article qualifies for 3 contact hours of continuing education credit from the Auburn University College of Veterinary Medicine. CE tests must be taken online at Vetlearn.com; test results and CE certificates are available immediately. Those who wish to apply this credit to fulfill state relicensure requirements should consult their respective state authorities regarding the applicability of this program.

1. Other than idiopathy, the most common cause of feline uveitis is

- a. an immune-mediated condition.
- b. neoplasia.
- c. trauma.
- d. infection.

2. Aqueous flare is caused by

- a. a hyperreflective tapetal fundus.
- b. a cataract.
- c. the presence of proteins within the anterior chamber.
- d. liquefaction of the vitreous.

3. Uveitis can result in

- a. glaucoma.
- b. diabetes mellitus.
- c. systemic hypertension.
- d. corneal ulcer.

4. Which statement regarding treatment of feline uveitis is true?

- a. Topical and systemic antiinflammatory drugs are recommended when corneal trauma is not present.
- b. Use of topical corticosteroids is always indicated, regardless of underlying cause.
- c. Topical tropicamide has a longer duration of action than topical atropine.
- d. Topical atropine or tropicamide is indicated only when a dilated pupil is observed.

5. Which of the following statements is correct with respect to FIV?

- a. It is found in North American cat populations only.
- b. All infected, unvaccinated cats develop signs of systemic disease.
- c. Euthanasia of all seropositive asymptomatic cats should be recommended.
- d. Cats are typically infected via bite wounds.

6. Which of the following statements is incorrect with respect to uveitis in cats?

- a. In as many as 70% of uveitis cases, no underlying etiologic agent is identified.
- b. If symptomatic treatment for uveitis is instituted quickly, recurrence is unlikely.
- c. Uveitis is a common feline ocular disease that can result in permanent blindness if not treated aggressively and quickly.
- d. Uveitis may involve any and all parts of the feline uvea, including the iris, ciliary body, and choroid.

7. Ocular clinical signs suggestive of feline anterior uveitis include

- a. scleral hyperemia, blepharospasm, and retinal detachment.
- b. aqueous flare, miosis, and low IOP.
- c. intraocular hemorrhage, elevated IOP, and retinal granuloma.
- d. corneal ulcer, mydriasis, and cataract.

8. Which statement is correct with regard to toxoplasmosis in cats?

- a. Recurrence of disease is unlikely with appropriate therapy.
- b. The parasite is transmitted through shared food and water bowls.
- c. Ocular signs of *Toxoplasma*-induced uveitis include multifocal, dark grey lesions in the tapetal fundus.
- d. The prevalence of toxoplasmosis in the feline population is estimated at 75%.

9. Which is the most common type of primary ocular neoplasia resulting in uveitis in cats?

- a. ciliary body adenoma
- b. lymphosarcoma
- c. sarcoma
- d. iris melanoma

10. Which statement regarding trauma-induced uveitis in cats is true?

- a. It can be caused by blunt or perforating trauma.
- b. It is only a consideration in cases of bilateral uveitis.
- c. It is uncommon except after ocular surgical procedures.
- d. It is easy to treat and has an excellent prognosis.