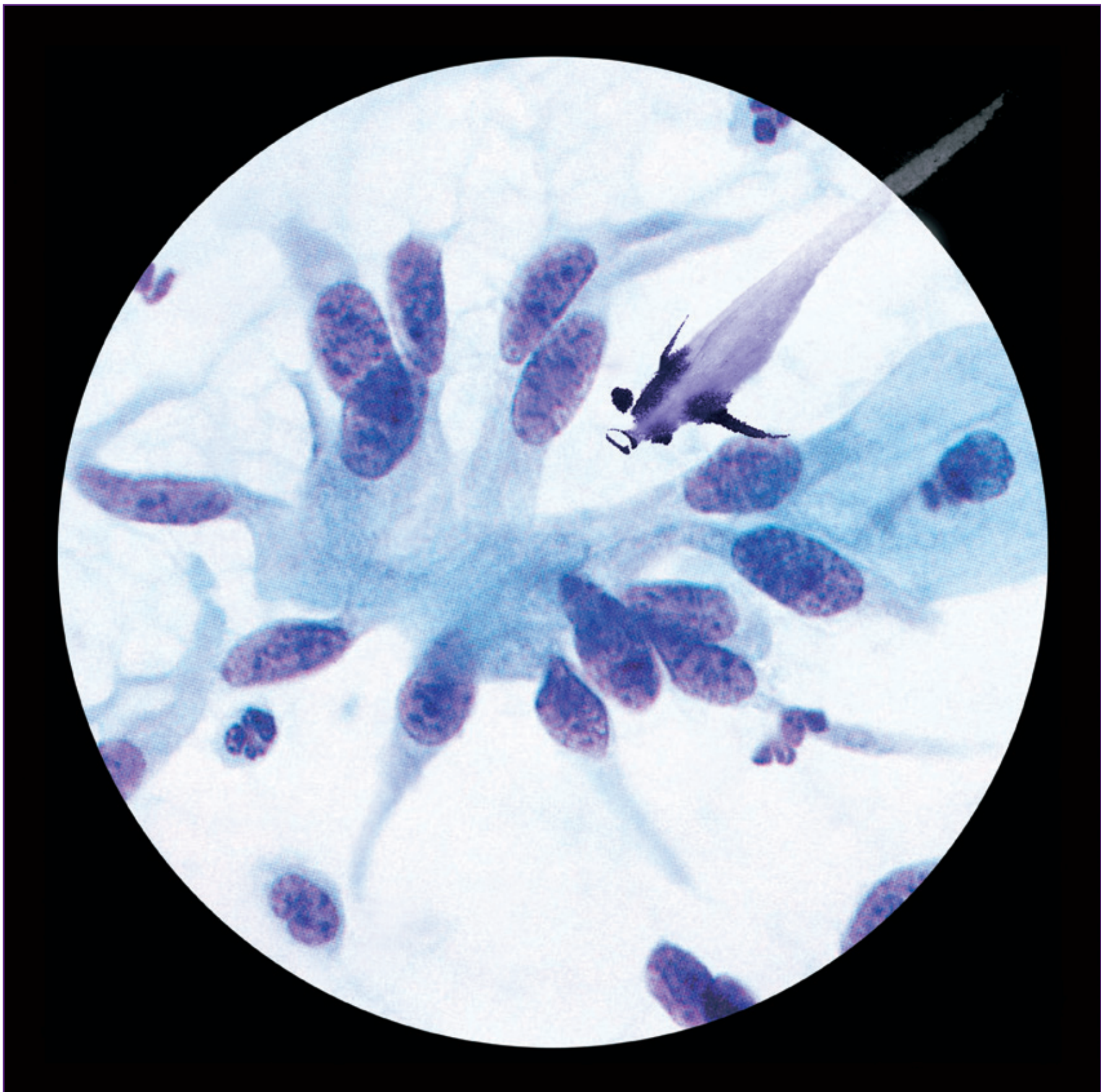


The Art & Science of Cytopathology

2nd Edition

(in 4 volumes)



To Laurie, with love

The Art & Science of Cytopathology

2nd Edition

Deep Aspiration Cytology

(Volume 3 of 4)

Richard Mac DeMay, MD
Professor of Pathology
Director of Cytopathology
University of Chicago



American Society for Clinical Pathology
Chicago

Acknowledgements

First and foremost, I want to acknowledge the Herculean (at times no doubt Sisyphean) effort of Joan Hives in doing the library research and bibliographic preparation work for this book. I am also grateful for her many personal kindnesses to me. Unfortunately, due to illness, Joan was unable to completely finish this immense task, but did well more than 90% of the total.

I thank my valiant wife, Valerie, who stepped up late in the going to help finish the bibliography. Even *just* 10% of 25,000 references is way more than you can shake a stick at...and probably adds to the “worse” side of that marriage vow.

I also want to acknowledge my long-time colleagues, Ann Marie Maslan (now retired) and Ward Reeves (of the famous and eponymous WARD cells) for their tremendous help and support over many years.

I am also lucky to have many other wonderful colleagues at the University of Chicago, including Thomas Krausz, Jeffrey Mueller, and Tatjana Antic, as well as Ghazal Khan, Patsy Lin, Sean Macleish, Rebecca Danahey, Phuong Lang, Raephaele Masirnille, and Minerva Torres.

In the course of the past 2 decades of work on this enterprise, many people have extended help with expertise and useful criticisms. But I have to extend special thanks to all who contributed a slide or photomicrograph in the amassing of those 50 thousand images from which we chose the final set. Important contributions of advice, time and/or materials came from Jerome Taxy, James Vardiman, Syed Ali, Lawrence Ash, Bernard Naylor, William Johnston, Karen Honeycutt via James Linder, Francis Chandler, John Watts, Jan Silverman, Blair Holladay, Marshall Austin, Kent Nowels, Jami Walloch, Elizabeth Sengupta, Fred Worsham, and Greg Spiegel.

Again, I thank Hector Battifora, Denise deFrias, and Jack Frable, 3 of my best teachers for sharing their knowledge and inspiring me to devote so much of my life's blood to cytopathology.

Last, but certainly not least, I thank Joshua Weikersheimer of ASCP, my friend and co-conspirator in the *Art & Science of Cytopathology* and all my other books. Once a man of taste and patience, he is now probably just a man of taste.

All of you have my deep appreciation and warm personal regards.

Publishing Team

Erik & Lisa Tanck (design/production)

Cristina Lazar (color consultant)

Jeffrey Link (production)

Aimee Algas (editorial/proofreading)

Joshua Weikersheimer (publishing direction)

Notice

Trade names for equipment and supplies described are included as suggestions only. In no way does their inclusion constitute an endorsement of preference by the Author or the ASCP. The Author and ASCP urge all readers to read and follow all manufacturers' instructions and package insert warnings concerning the proper and safe use of products. The American Society for Clinical Pathology, having exercised appropriate and reasonable effort to research material current as of publication date, does not assume any liability for any loss or damage caused by errors and omissions in this publication. Readers must assume responsibility for complete and thorough research of any hazardous conditions they encounter, as this publication is not intended to be all-inclusive, and recommendations and regulations change over time.



American Society for
Clinical Pathology
Press

Copyright © 2012 by the American Society for Clinical Pathology. All rights reserved. No part of this publication may be reproduced, stored in a retrieval system, or transmitted in any form or by any means, electronic, mechanical, photocopying, recording, or otherwise, without prior written permission of the publisher.

Printed in Hong Kong

16 15 14 13 12

Table of Contents: Volume 3—Deep Aspiration Cytology

15: Pleura, Pericardium, Peritoneum

The Cells 1146

Nonneoplastic Diseases 1146

Inflammation/Infection 1146

Neoplasms 1147

Benign Tumors 1147

Malignant Tumors 1149

Metastases 1152

Synoptic Atlas 1153

16: Lung

Fine Needle Aspiration Biopsy 1156

Introduction 1156

Transbronchial (Wang) Needle Aspiration Biopsy 1158

The Cells 1159

Alveolar Cells 1159

Bronchial Cells 1160

Kulchitsky Cells 1160

Mesothelial Cells 1160

Miscellaneous Cells 1160

The Solitary Pulmonary Nodule 1160

Benign Diseases of the Lung 1161

Inflammatory Disease 1161

Lipid Pneumonia 1164

Pulmonary Infarct 1164

Miscellaneous Benign Conditions 1165

Benign Neoplasms of the Lung 1167

Malignant Diseases of the Lung 1170

Clinical Features of Lung Cancer 1171

Cytologic Diagnosis of Lung Cancer 1173

Synoptic Atlas 1203

17: Mediastinum

FNA Biopsy of Mediastinum 1218

The Cells 1219

Cells You Don't Want to See 1219

Diseases of the Mediastinum 1219

Mediastinal Cysts 1219

Inflammation 1221

The Thymus and Its Diseases 1222

Thymic Hyperplasia 1222

Thymoma 1223

Germ Cell Tumors 1230

Seminoma (Germinoma) 1231

Teratomas 1231

Embryonal Carcinoma 1232

Yolk Sac (Endodermal Sinus) Tumor 1232

Choriocarcinoma 1232

Lymph Node 1233

Reactive Hyperplasia 1233

Castleman Disease (Angiofollicular Hyperplasia) 1233

Malignant Lymphoma 1234

Neurogenic Tumors 1235

Sympathetic Nervous System Tumors 1236

Peripheral Nervous System Tumors 1236

Paraganglioma 1237

Mesenchymal Tumors 1238

Thymolipoma 1238

Solitary Fibrous Tumor 1238

Liposarcoma 1239

Other Soft Tissue Tumors 1239

Ectopic Thyroid and Parathyroid 1239

Thyroid 1239

Parathyroid 1239

Metastases 1239

Synoptic Atlas 1240

18: Liver

The Cells 1249

- Hepatocytes 1249
- Bile Duct Cells 1250
- Miscellaneous Cells 1250

Inclusions and Pigments 1251

- Inclusions 1251
- Pigments 1252

Diffuse Liver Diseases 1253

- Hepatitis 1253
- Cirrhosis 1254
- Nodular Regenerative Hyperplasia 1255

Nodular Liver Diseases 1255

- Cysts 1255
- Abscess 1256
- Granuloma 1256
- Extramedullary Hematopoiesis 1257
- Benign Tumors 1257
- Malignant Tumors 1260
- Mesenchymal Tumors 1274

Synoptic Atlas 1280

19: Pancreas

FNA Biopsy of the Pancreas 1298

- The Cells 1300

Diseases of the Pancreas 1303

- Pancreatitis 1303
- Nonneoplastic Cysts 1306
- Neoplastic Cysts 1307
- Solid Neoplasms 1313

Extrahepatic Biliary Tract and Gallbladder 1326

Synoptic Atlas 1327

20: Kidney

Introduction 1346

The Cells 1347

- Tubular Cells 1347
- Glomeruli 1348
- Miscellaneous Cells 1348

Benign Diseases of the Kidney 1348

- Some Miscellaneous Renal Conditions 1348
- Renal Cysts 1348
- Renal Abscess 1350
- Xanthogranulomatous Pyelonephritis 1350
- Renal Infarct 1351
- Benign Neoplasms 1351

Malignant Diseases of the Kidney 1355

- Renal Cell Carcinoma 1355
- Urothelial Carcinoma of the Renal Pelvis 1364
- Lymphoma 1365
- Mesenchymal Neoplasms 1365
- Metastasis 1366
- Malignant Renal Tumors of Childhood 1366

Synoptic Atlas 1371

21: Adrenal

Introduction 1384

- Adrenal Cortex 1384
- Adrenal Medulla 1385

Incidental Adrenal Nodules 1385

- Without a Known History of Cancer 1385
- With a Known History of Cancer 1385
- Evaluation of Incidentalomas 1386

FNA Biopsy of Adrenal Lesions 1386

Adrenal Cortex 1386

- The Cells 1386
- Adrenal Cysts 1387
- Inflammatory Lesions 1388
- Adrenal Myelolipoma 1388
- Hyperplasia, Adenoma, and Adenomatous Nodules 1389
- Adrenal Cortical Carcinoma 1390
- Adrenal Cortical Syndromes 1393

Adrenal Medulla 1393

- The Cells 1393
- Pheochromocytoma and Paragangliomas 1394
- Neuroblastoma, Ganglioneuroblastoma, and Ganglioneuroma 1396
- Metastases 1397

Synoptic Atlas 1399

22: Gonads (Naughty Bits)

Testis and Male Genital 1406

- The Cells 1406
- Cysts, Inflammations, and Neoplasms 1407

Prostate 1408

The Cells 1408

- Epithelial Cells 1408
- Basal Cells 1408
- Atypical Benign Cells 1408
- Benign Diseases of the Prostate 1409
- Malignant Diseases of the Prostate 1409
- Other Prostatic Neoplasm 1410
- Gonadal Sex Cord Stromal Tumors 1411
- Germ Cell Tumors 1414
- Mixed Germ Cell Tumors 1419

Ovary and Female Pelvis 1419

- Ovarian Cysts 1420
- Ovarian Epithelial Tumors 1422
- Miscellaneous Female Genital Tract Neoplasms 1426

Synoptic Atlas 1427

23: Central Nervous System

Reactive and Inflammatory Lesions 1438

- Infections 1438
- Pseudotumoral Macrophage-Rich Lesions 1440

Lesions of the Sellar Region 1441

- Craniopharyngioma 1441
- Rathke Cleft Cyst 1442
- Benign Cysts 1442
- Colloid Cyst of the Third Ventricle 1442

Meningeal and Choroid Plexus Tumors 1443

- Meningioma 1443
- Hemangiopericytoma 1443
- Choroid Plexus Papilloma/Carcinoma 1443

Major Gliomas 1444

- Low-Grade Astrocytoma 1444
- Anaplastic Astrocytoma 1444
- Glioblastoma Multiforme 1444
- Oligodendroglioma 1445

Variants/Subtypes of Glial Tumors 1445

- Pilocytic Astrocytoma 1445
- Pleomorphic Xanthoastrocytoma 1446
- Gliomatosis Cerebri 1446
- Small Cell Glioblastoma Multiforme 1446
- Gliosarcoma 1447
- Granular Cell Astrocytoma 1447

Other Gliomas 1447

- Ependymoma 1447
- Myxopapillary Ependymoma 1448

Embryonal Tumors 1448

- Atypical Teratoid/Rhabdoid Tumor 1448
- Medulloblastoma 1448
- Primitive Neuroectodermal Tumor 1449

Germ Cell Tumors 1449

Neuronal Tumors 1450

- Central Neurocytoma 1450

Lesions of the Pineal Region 1450

- Pineocytoma and Pineoblastoma 1450

Hematopoietic and Metastatic Tumors 1450

- Primary Lymphoma 1450
- Metastatic Cancers 1451

Synoptic Atlas 1452

24: Bugs: A Micromiscellany of Microbiology

Viruses 1466

- Adenovirus 1466
- Cytomegalovirus 1466
- Herpes Simplex Virus 1467
- Varicella-Zoster (Herpes Zoster) 1467
- Human Papillomavirus 1467
- Measles Virus 1467
- Molluscum Contagiosum 1467
- Respiratory Syncytial Virus 1468

Bacteria 1468

Fungus 1470

- Alternaria 1470
- Aspergillus* species 1470
- Blastomyces (dermatitidis)* 1471
- Candida (albicans and Other Species)* 1471
- Coccidioides immitis* 1471
- Cryptococcus neoformans* 1471
- Geotrichum candidum* 1472
- Histoplasma capsulatum* 1472
- Paracoccidioides brasiliensis* 1472
- Zygomycetes (Mucor, Rhizopus, Absidia, etc)* 1472
- Pneumocystis jirovecii* 1472
- Other Fungi 1473

Parasites 1473

- Protozoans 1473
- Helminths (Worms) 1476

Arthropods 1477

- Lice 1477
- Scabies 1477

Contaminants 1478

25: The Cell

The Cell in Health and Disease 1480

The Nucleus 1480

The Cytoplasm 1483

The Cell Membrane 1488

The Extracellular Matrix 1491

The Cell Cycle 1491

Carcinogenesis 1492

- Diagnostic Features of Malignancy 1493

Synoptic Atlas 1496

26: Stains

Routine Stains 1504

- Papanicolaou (Pap) Stain 1504
- Romanowsky Stain 1505

Fixation 1505

Special Stains 1505

- Alcian Blue Stain 1505
- Mucicarmine Stain 1506
- Periodic Acid-Schiff (PAS) Stain 1506
- Lipid Stains 1506
- Masson Trichrome 1506
- Melanin Stains 1506
- Chromaffin, Argentaffin, and Argyrophil Stains 1506
- Congo Red Stain 1506
- Methyl Green Pyronine (MGP) Stain 1506
- Phosphotungstic Acid-Hematoxylin (PTAH) Stain 1506
- Copper Stains 1507

Enzyme Reactions 1507

- Acid Phosphatase 1507
- Alkaline Phosphatase 1507
- Aryl Sulfatase 1507
- Aminopeptidase 1507
- Lysozyme 1507

**Immunohistochemistry: Brown Stains
and “Magic Markers” 1507**

- Adhesion Molecules 1509
- Calcium-Binding Proteins 1510
- Cell Membrane Antigens 1510
- Cluster of Differentiation (CD) Molecules 1511
- Connective Tissue Proteins 1512
- Cytoskeleton-Associated Actin Binding Proteins 1512
- Endothelial Proteins 1512
- Enzymes 1512
- Fusion Proteins 1513
- Growth Factors and Growth Factor Receptors 1513
- Hormones 1514
- Hormone Receptor Proteins 1514
- Immunoglobulins 1514
- Filaments 1514
- Melanocytic Proteins 1517
- Mucin and Glycoprotein Antigens 1517
- Muscle and Contractile Proteins 1518
- Neuroendocrine Secretory Granule Matrix Proteins 1519
- Oncogene Proteins 1519
- Proliferation Markers/Cell Cycle
Regulators/Apoptosis Markers 1519
- Protease Inhibitors 1519
- Synaptic Vesicle-Associated Proteins 1520
- Transcription Factors 1520
- Transmembrane Glycoproteins 1521
- Tumor Suppressor Gene Proteins 1522
- Other Markers 1522

**Uranyl Acetate + Lead Citrate Stain (Electron
Microscopy) 1524**

27: Molecular Cytopathology

Techniques and Main Applications 1528

- Immunocytochemistry 1528
- Flow and Image Cytometry 1528
- Genomic Techniques 1529

Specimen Collection, Fixation, and Controls 1531

**Diagnostic, Prognostic, and Theranostic
Applications 1532**

- Lymphomas 1532
- Sarcomas of Adults and
Childhood Tumors 1534
- Other Tumors 1534
- Infectious Pathogens 1535

Case Examples 1536

28: The Laboratory

Quality Control and Quality Assessment 1541

- Quality 1541
- Quality Control 1541
- Quality Assessment 1541
- Analyzing Quality Control and Quality Assessment Activities 1542

Specimen Collection 1542

- Fresh Body Cavity Fluids: Let Them Clot or Not? 1545

Slide Preparation 1545

- Direct Smears 1545
- Membrane Filtration 1546
- Cytocentrifugation 1547
- Liquid-Based Preparations 1547

Fixation 1548

- Gynecologic and Fine Needle Aspiration 1550
- Nongynecologic 1550
- Technical Notes and Tips 1551

Papanicolaou Stain 1552

- Materials and Methods 1552
- Gill Hematoxylin 1553
- Results 1556
- Rinses 1559
- Quality Assessment Using Buccal Smears 1560
- Destaining 1561
- Troubleshooting 1562

Mounting 1563

- Xylene 1566
- Molecular Sieves 1567
- Brown Artifact (aka “Cornflaking”) 1568

Microscopy 1569

- Tips 1569
- Techniques 1569
- Timing 1570

- As Needed 1570
- Köhler Illumination 1570
- Results 1571
- Discussion 1571

Screening 1571

- SPADE: Screening Protocol to Assist Detection 1573
- The 4× Objective 1574
- Ink Dots 1574
- Percent Overlap 1574
- Eyepiece Field Number 1575
- Conspicuity Area 1576
- Vigilance and Vigilance Decrement 1577
- Conclusion 1577

Data Analysis 1578

- Calculating False Negative Proportion (Estimated) 1579
- 100% Rapid Review vs 10% Slow Review (ie, CLIA '88 10% Review) 1581
- Rapid Prescreening 1582
- Conclusion 1583

Regulatory 1583

- CLIA '88 1583
- OIG Compliance Program Guidance for Clinical Laboratories 1588
- Compliance Resources 1591
- HIPAA 1591

29: The Microscope

Resolution, Magnification, and Contrast 1594

- Resolution 1594
- Magnification 1594
- Contrast 1595

Lenses 1595

- Diffraction 1596
- Numerical Aperture 1597
- Aberrations 1599
- Music to Your Eyes 1600
- More Considerations 1601

Oculars 1601

Objectives 1601

Substage Condenser 1602

Köhler Illumination 1603

30: Statistics (Lies, More Lies, and...)

What Is “Normal”? 1606

What Does a Diagnosis Really Mean? 1606

By What Means Can the Degree of Certainty—the Shades of Gray—Be Measured? Statistics 1606

The Gold Standard 1606

The Statistical Importance of Clinical History 1607

Of True and False Negative and Positive Tests 1608

Of Sensitivity and Specificity 1608

Predictive Value and Diagnostic Accuracy 1609

Positive Predictive Value 1609

Negative Predictive Value 1609

Diagnostic Accuracy 1609

Likelihood Ratios 1610

Receiver Operating Characteristic Curves 1610

Summary 1611

Rejecting the Null Hypothesis 1611

Screening vs Diagnostic Tests 1612

Significance of Suspicious, Unsatisfactory, and Nondiagnostic Findings 1612

The Birthday Problem: Unlikely Events and Their Concurrence 1612

Epidemiologic Studies 1613

Of Order and Chaos 1613

The Law of Parsimony 1613

π: The History of Cytology

Etymology 1616

The History of Cytopathology 1616

Prehistory and Ancient Medicine 1616

Science Began on May 28, 484 BCE 1616

History of the Microscope 1618

Antiquity 1619

Classical Greco-Roman Civilization 1619

Middle Ages 1619

The Renaissance 1620

18th Century 1622

Correction of Aberrations 1623

19th Century 1624

Toward the Cell Theory 1625

History of Cytodiagnosis 1627

Brief History of FNA Biopsy 1632

Index ix1



Omne tulit punctum qui miscuit utile dulci, lectorem delectando pariterque monendo

—Horace, from the *Ars Poetica*

In other words, a spoonful of sugar helps the medicine go down. That was the watchword for the first edition of the *Art & Science of Cytopathology*, and the tradition continues in this completely revised and rewritten new second edition. *Useful* knowledge is still best assimilated when rendered *sweet* to the reader. So we have tried to find ways to *delight* and *instruct* the reader simultaneously. The features that made the original edition of the *Art & Science* useful and sweet are still here (and in even more droves): thousands of images, hundreds of summary lists (MaxFax), and scores of tables, including image-based tables that couple morphologic descriptions with real microscopic appearances. The microscopic imaging ranges from scanning to oil immersion magnifications, revealing diagnostic detail in Papanicolaou and Romanowsky stains, along with immunocytochemical, liquid-based, molecular, and special stain preparations as most useful. As before, each diagnostic chapter features a synoptic atlas of large images that are carefully chosen and described to facilitate quick review (perhaps for board exams?).

The 4 volumes are arranged by general topic. Volume 1 is Exfoliative Cytology, Volume 2 is Superficial Aspiration Cytology, and Volume 3 is Deep Aspiration Cytology. Volume 3 also includes an Excursus from pure cytodiagnostics comprising chapters on microbiology, the cell, stains, the microscope, statistics, and history of cytology—as well as new contributed chapters on lab operations and regulation, and molecular cytopathology. Finally, we've created a supportive Volume 4 in which are found the references for all of the chapters—over 25,000 of them—together with a master comprehensive index that complements the volume-specific indices found in the other 3 volumes. So you have an extraordinarily comprehensive bibliography of cytopathology, yet you only have to handle it when you specifically need the full citations.

So what's new in the 15 years since the first edition's debut? Well, the digested contents of over 15,000 new articles selected—about 1,000 per year—that have been published since the release of the original edition. That's a lot of new information. Classification schema have changed over the years, taking an increasingly molecular turn. The text reflects the twistings and turnings of various classification systems, such as the Bethesda systems, the 2008 WHO hematologic classification, and—hot on the presses—the latest diagnostic system for carcinoma formerly classified as bronchioloalveolar carcinoma. But the book is careful to relate well-established approaches to diagnosis and widely used nomenclature with the most current proposed schemes—nothing useful and familiar is discarded simply because it is not strictly *au courant*.

All of the photomicrographs retained from the first edition were reimaged to take advantage of new digital imaging techniques. In addition, new images were chosen from over 50,000 new

photomicrographs to fill gaps, increase the degree of variation that could be displayed, and to show some exotics that have rarely been seen in textbooks of cytopathology before now. We've also modified materials and design to make each volume easier to handle and a little less heavy, and yet more image- and information-packed page after page than the original edition (7,000 images alone!).

But we haven't lost track of the art amidst all that new science. Indeed, the *art* in *The Art & Science* has inspired others over the years to see opportunities for their own art in science. The frontispieces of each of the first 3 volumes display some of the work of Henry Li, who combines a little Chinese brushwork with photomicrography. We are gratified to see how this work has touched so many others around the world.

We hope that this new edition will continue to be a practical storehouse of information for everyday problems that is also a pleasure to use, and that it will enhance the art & science of your ongoing cytologic practice. *Let us advance knowledge so that life may be enriched.*

Mac DeMay

Joshua Weikersheimer

Mac begins writing (c 1958 CE) with Laurie advising

