

## Use of GuideLiner Catheter for Anomalous Right Coronary Artery Angiography and Intervention

P. Kasi Ramanathan, MD and Roberta Redfern, PhD

**ABSTRACT:** We report a case of the use of the GuideLiner catheter during transfemoral diagnostic angiography and intervention of an anomalous right coronary artery (RCA) after unsuccessful attempts to cannulate the RCA with other catheters. The GuideLiner catheter was successfully employed to coaxially engage the ostium of the RCA. Thrombotic disease appeared to be responsible for non-ST elevation myocardial infarction. The GuideLiner catheter allowed visualization of the lesions and delivery of the stent in an anomalous RCA which could not have been otherwise coaxially engaged.

J INVASIVE CARDIOL 2013;25(1):E20–E22

**Key words:** anomalous right coronary artery

---

Coronary arteries of anomalous origin are uncommon and are associated with increased risk of atherosclerotic disease as well as angina pectoris, myocardial infarction, and sudden death, even in the absence of atherosclerosis.<sup>1,2</sup> These arteries present unique challenges to interventionalists due to several technical factors as a result of the abnormal origin and course of the artery, and require careful selection of guide catheters.<sup>3,4</sup> One recently developed device, the GuideLiner catheter, specifically addresses difficult cases, particularly when other catheters have failed.<sup>5</sup> Here, we describe the use of the five-in-six system for angiography and intervention in an anomalous right coronary artery (RCA).

### Case report

A 58-year-old man with non-ST elevation myocardial infarction (NSTEMI) presented to our institution with chest pain and a positive troponin. He was referred for catheterization in the setting of ongoing mild 2/10 chest pain. Diagnostic angiography revealed mild non-obstructive coronary disease in the left main, left anterior descending, and a non-dominant left circumflex artery.

Multiple diagnostic catheters were used unsuccessfully to cannulate the RCA. An aortic root injection revealed the presence of the RCA, but the origin from the aorta was unclear. Review of the left coronary images suggested that the RCA may be originating from the left coronary cusp superior to the left main artery.

Employing a femoral approach, a 6 Fr AL 0.75 guide catheter (Cordis Corporation) was used initially to engage the left main artery. It was carefully lifted superior to the left main and non-selective catheter injection showed the RCA to originate superior to the left main (Figure 1A).

There was thrombotic disease in the RCA, which likely led to the NSTEMI. Given the take-off of the vessel, the RCA could not be selectively engaged. After therapeutic doses of bivalirudin were given for anticoagulation, a 0.14 Fielder Wire (Asahi) was used to cross the lesions in the RCA (Figure 1B). Attempts were made to use the wire down the coronary as a rail to coaxially engage the RCA, but were unsuccessful. A 1.5 mm balloon was advanced down the vessel, over which a 6 Fr GuideLiner catheter was carefully used to selectively coaxially engage the ostium of the RCA (Figure 1C). Angiography revealed severe thrombotic disease in the RCA. Intracoronary IIb/IIIa inhibitors were given as well as verapamil and adenosine. Given the size of the GuideLiner catheter (5 Fr in 6 Fr guide), it was not possible to use a manual thrombectomy catheter. The lesions were stented with two Integrity bare-metal stents (Medtronic), 4.0 x 26 proximally and 3.5 x 30 mid. Finally, angiography revealed brisk flow and no residual and the patient's chest pain had abated (Figure 1D). Intervention time and amount of contrast used were minimized by use of the GuideLiner catheter.

## Discussion

Though stent delivery is unsuccessful in only approximately 5% of cases, many new devices and techniques have been developed in recent years to be used in the setting of technically difficult interventions, such as supporting guiding catheters, lower-profile stents, buddy wires for coaxiality, the buddy balloon technique, and the anchor technique. The GuideLiner catheter is one of the newest devices developed specifically for difficult cases. This catheter has a coaxial guide extension with rapid exchange which allows for deep seating of the extension into the vessel for additional back-up guiding catheter support.<sup>5,6</sup> Furthermore, the device provides coaxial alignment in cases where the coronary ostium take-off prevents the placement of a guiding catheter.<sup>5</sup>

Since its first reported in-man use in 2010,<sup>7</sup> the GuideLiner has been used for angiography in the setting of tortuous arteries, anomalous left main coronary arteries, and chronic total occlusions, among others.<sup>8-11</sup> Pershad et al recently reported the six clinical uses of the GuideLiner catheter, as well as tips and tricks for successful intervention.<sup>5</sup> Here, we suggest an additional use of the GuideLiner in angiography and intervention for thrombotic disease in an anomalous RCA originating from the left coronary cusp superior to the left main artery. Users should remain ever conscious of possible plaque disruption and vessel dissection while using this device.

## Conclusion

This case highlights a unique role of the Guideliner catheter in anomalous coronary angiography and intervention. The GuideLiner catheter allows for coaxial engagement and adequate back-up support for this complex intervention.

## References

1. Sarkar K, Sharma SK, Kini AS. Catheter selection for coronary angiography and intervention in anomalous right coronary arteries. *J Interv Cardiol.* 2009;22(3):234–239.
2. Rudan D, Todorovic N, Starcevic B, et al. Percutaneous coronary intervention of an anomalous right coronary artery originating from the left coronary artery. *Wien Klin Wochenschr.* 2010;122(15–16):508–510.
3. Cola C, Miranda F, Vaquerizo B, et al. The Guideliner catheter for stent delivery in difficult cases: tips and tricks. *J Interv Cardiol.* 2011;24(5):450–461.
4. Vijayvergiya R, Grover A, Singhal M. Percutaneous revascularization in a patient with anomalous origin of left main coronary artery. *World J Cardiol.* 2011;3(9):311–314.
5. Pershad A, Sein V, Laufer N. GuideLiner catheter facilitated PCI—a novel device with multiple applications. *J Invasive Cardiol.* 2011;23(11):E254–E259.
6. Luna M, Papayannis A, Holper EM, et al. Transfemoral use of the guideLiner catheter in complex coronary and bypass graft interventions. *Catheter Cardiovasc Interv.* 2011 Jul 29. (Epub before print).
7. Mamas MA, Fath-Ordoubadi F, Fraser DG. Distal stent delivery with GuideLiner catheter: first in man experience. *Catheter Cardiovasc Interv.* 2010;76(1):102–111.
8. Moynagh A, Garot P, Lefevre T, Louvard Y. Angiographic success and successful stent delivery for complex lesions using the GuideLiner five-in-six system — a case report. *Am Heart Hosp J.* 2011;9(1):E44–E47.
9. Park CI, Noble S, Bonvini RF. GuideLiner microcatheter to improve back-up support during a complex coronary stenting procedure through a tortuous left internal mammary graft. *J Invasive Cardiol.* 2012;24(4):E77–E79.
10. Serajian A. Novel use of a GuideLiner catheter to visualize distal LAD after LIMA anastomosis in selective coronary angiography. *J Invasive Cardiol.* 2012;24(2):E30–E31.

11. Thomas JA, Patel J, Latif F. Successful coronary intervention of circumflex artery originating from an anomalous left main coronary artery using a novel support catheter: a case report and review of literature. J Invasive Cardiol. 2011;23(12):536-539.

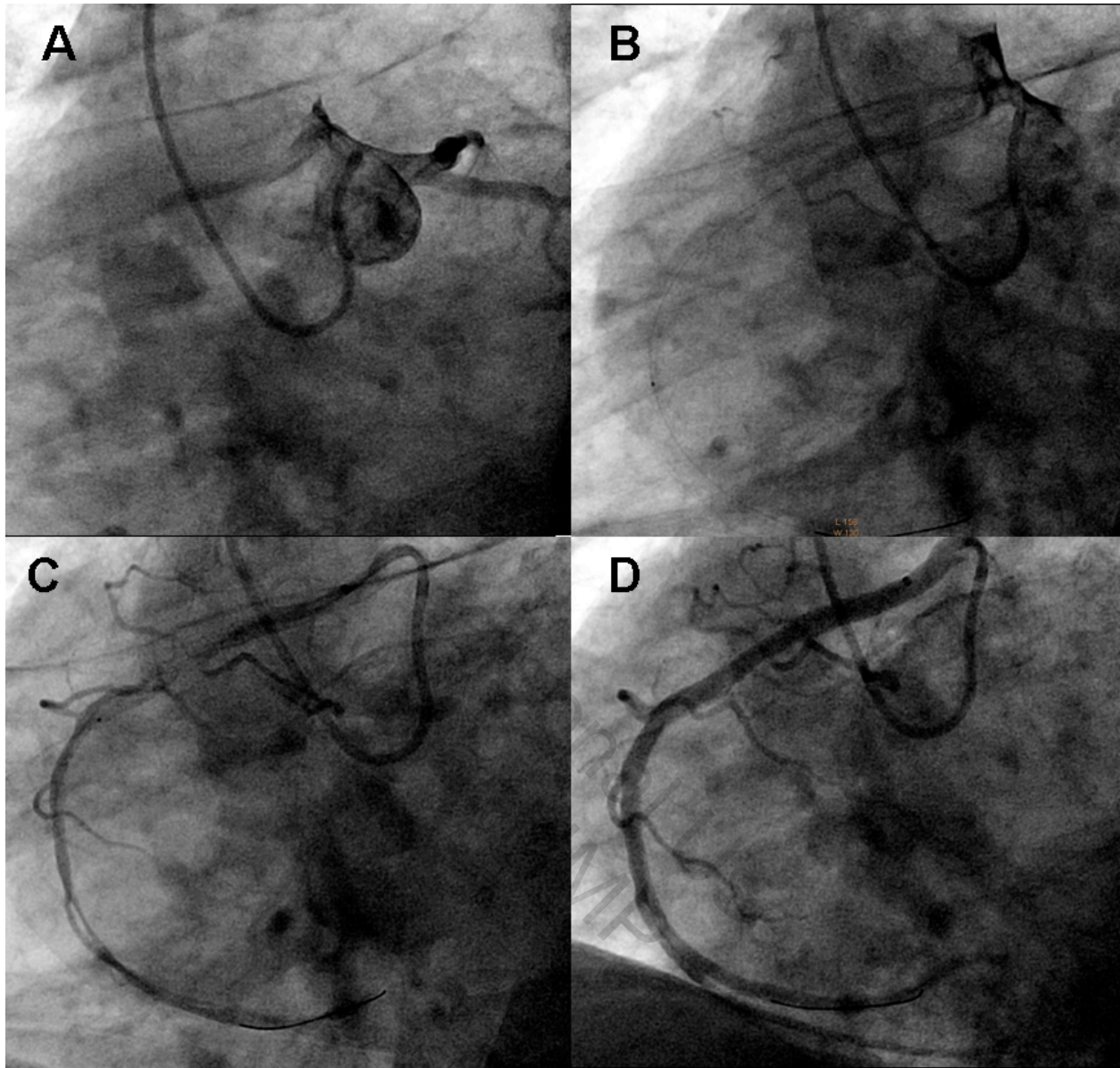
---

From the Northwest Ohio Cardiology Consultants, ProMedica Heart and Vascular Institute, The Toledo Hospital, ProMedica Health System, Toledo, Ohio.

Disclosure: The authors have completed and returned the ICMJE Form for Disclosure of Potential Conflicts of Interest. The authors report no conflicts of interest regarding the content herein.

Manuscript submitted June 25, 2012, provisional acceptance given July 6, 2012, final version accepted July 25, 2012.

Address for correspondence: P. Kasi Ramanathan, MD, FACC, FSCAI, Northwest Ohio Cardiology Consultants, ProMedica Heart and Vascular Institute, The Toledo Hospital, ProMedica Health System, 2940 N. McCord Road, Toledo, OH 43615. Email: Kasi\_ramanathan@yahoo.com



**Figure 1.** The AL 1 guide catheter was used, but given the anomalous origin, this could not coaxially align with the native vessel to provide adequate support for delivery of the stent. (A) Left coronary artery engaged, determining the origin of the right coronary artery (RCA) superior to the left main. The GuideLiner was anchored by having the AL 1 guide catheter close to the anomalous RCA, and placing the 0.14 wire down the RCA. (B) Fielder wire crossing lesions in right coronary artery. The 1.5 mm balloon was advanced into the RCA and the guideliner was railed over the 1.5 mm balloon and anchored into the proximal RCA providing coaxial support. (C) GuideLiner selectively coaxially engaging the ostium of the RCA until (D) improved flow following angiography.