

Descending Septal Artery: An Important Artery For Collateral Coronary Circulation

Kintur Sanghvi, MD¹, Sarah de Leon Mansson, DO¹, Tejas Patel, MD²

Abstract: We present a case report of a 40-year-old male who underwent elective cardiac catheterization secondary to complaints of intermittent chest pain and inducible ischemia in the anterior wall. Diagnostic catheterization revealed severe coronary artery disease including an occluded mid left anterior descending (LAD) artery. There was a rarely described descending septal artery (Bonapace's branch) originating from a separate ostium in the right aortic sinus. This artery was a very important source of collateralization to the LAD. This artery has been reported once in vivo, while it has been described more frequently in postmortem studies. The descending septal artery is postulated to have an important role in the perfusion of the conduction system and in collateral circulation in patients with coronary artery disease. A literature review confirms the functional importance of this artery.

J INVASIVE CARDIOL 2013;25(2):E30–E32

Key words: anomalous artery, Bonapace's branch, descending septal branch, right superior septal artery

The descending septal artery (DSA) is an accessory coronary artery that is rarely reported on coronary angiography.¹ We are reporting a case where the DSA played a crucial role of providing collateral circulation to an occluded left anterior descending (LAD) artery.

Case report

A 40-year-old male patient with past medical history of non-insulin dependent diabetes mellitus, hyperlipidemia, and active smoking presented with complaints of intermittent chest pain for 2 years. A transthoracic echocardiogram revealed normal regional left ventricular wall motion and thickening. During an exercise nuclear stress test, there were 1 mm ST-segment depressions at peak exercise. These ST segment changes quickly resolved within a minute of recovery. He was able to complete 10.1 metabolic equivalents exercise. Myocardial perfusion imaging revealed a moderate severity, reversible perfusion defect of moderate to large size involving the mid and distal portion of the anterior

wall. There was a small area of severe reversible ischemia involving the true apex.

Elective cardiac catheterization was done through a right radial artery approach. A 5Fr access system was utilized, and a 5 Fr Tiger 4.0 catheter (Terumo Corporation) was used to perform selective coronary angiogram and left ventriculogram. During attempts to cannulate the right coronary artery (RCA), the Tiger catheter engaged in what appeared to be an anomalous artery originating from the right coronary cusp. Multiple orthogonal angiograms of this artery were performed. After literature review, we have interpreted this artery to be a DSA (Bonapace's branch). The LAD was occluded at the origin of the first diagonal branch (Figure 1). There were two collateral systems supplying the LAD. These were: (1) the DSA originating from the right coronary cusp giving collaterals to the septal branch and filling the LAD to the apex (Figures 2 and 3); and (2) collaterals from the conus branch of the RCA reaching the first septal branch of the LAD (Figures 3 and 4). Both collateral systems were small in size. The dominant RCA had a focal segment of 60%–70% stenosis (Figure 4). Left ventricular systolic function was normal. The left circumflex (LCX) had mild disease. The patient underwent successful bypass surgery with grafts to the LAD as well as RCA and had uneventful recovery.

Discussion

The artery we thought was an anomalous branch is described in the literature as the “descending septal artery,” “descending septal branch,” “right superior septal artery,” or “Bonapace's branch.”

We found only one case report of a descending septal branch originating from the RCA on the literature review. The artery was described as coursing in to the middle of the interventricular septum toward the cardiac apex.² There are also a few descriptions of this artery in postmortem angiographic studies and pathological examinations.^{3–5}

In the case reported² as the first in vivo description of the descending septal branch, the patient had no significant coronary artery disease. The descending septal branch originated from the RCA in that patient. The artery was described as 1 mm size and supplied the posterior and basal two-thirds of the interventricular septum. Our patient had severe coronary artery disease and the DSA originated from a separate ostium in the right coronary cusp, but had a similar size and distribution.

In a postmortem angiographic study, Rodriguez et al³ described an accessory artery that helped supply the cardiac interventricular septum in 12% of human hearts and up to 66% of the hearts in other animal species. The described artery originates close to the right coronary orifice, descends through the superior septal border, and ramifies in the interventricular septum. The vessel was referred to as the “descending septal artery.” The DSA was described as arising from the first centimeter of the RCA, from a common orifice with the RCA, a common orifice with

the conus branch, or from an independent ostium in the right coronary cusp. The DSA was two times more likely to be present if there was coronary artery occlusion. The authors concluded that this branch is more likely to be a potential source of collateral circulation, and the artery has not gained the attention it deserves. Our patient had severe occlusive coronary artery disease with preserved left ventricular function. Another postmortem stereoscopic radiography study⁴ performed to understand the blood supply of the conduction system described the descending septal branch as supplying the proximal conduction system in 68% of human hearts studied. The author studied 112 human hearts and half of the patients with the descending septal branch had severe coronary disease. The descending septal branches arose directly from the RCA, from the first conal branch of the RCA, or from a separate aortic ostium in 58%, 25%, and 16.7% of the patients, respectively. Anastomosis was observed between the DSA and septal branches of the LAD artery in hearts with severe coronary artery disease. Our patient's angiography revealed a significant collateral circulation to an occluded LAD from the DSA (Figures 2 and 3). Failure to identify the target on the LAD might have compromised the treatment of our patient.

Said² reported after an extensive literature review that the descending septal branch is missing in textbooks of coronary anatomy and cardiology, as well as in papers dealing with coronary circulation. Ludinghausen⁵ found right superior septal artery (SSA) in 27% of the human heart dissections. The description of the SSA is consistent with that of the DSA. He described the artery as small in diameter, short, and with a variable origin. For that reason, it is difficult or almost impossible to visualize angiographically.⁵ This artery can be easily overlooked when the catheter tip is beyond the first few millimeters of the right coronary ostium, especially if the DSA originates from the RCA or from a common ostia of the RCA or conus artery. Our recognition of this branch may be related to the active catheter manipulation from the right radial approach or the use of a TIGER catheter, which has a side hole. This probably is the first case demonstrating the functional significance of the DSA in vivo.

Conclusion

For an interventional cardiologist, knowledge of the DSA is important for the following reasons: (1) this rarely reported coronary accessory branch probably serves a significant role in providing collateral flow in severe coronary artery disease patients and in perfusing the myocardial conduction system; (2) as in the described case report, DSA angiogram can help determine the distal target for surgical or percutaneous revascularization. Because of its size, the DSA may only allow selective cannulation with a 5 Fr guide catheter, but that can potentially be used for retrograde wiring of the chronic total occlusion; and (3) selective

cannulation of the RCA with a guide without side holes can compromise flow in the DSA originating from the very proximal RCA.

Evolving technology and use of computed tomography angiography can help expand our knowledge about the prevalence and predictors of the DSA, which has primarily been described only in postmortem studies.

References

1. Yamanaka O, Hobbs RE. Coronary artery anomalies in 126,595 patients undergoing coronary arteriography. *Cathet Cardiovasc Diagn*. 1991;21(1):28–40.
2. Said M, Muhlberger VA. The descending septal branch (Bonapace's branch). A case report and literature review of this often forgotten branch. First description in vivo. *Eur Heart J*. 1995;16(10):1443–1447.
3. Rodriguez FL, Robbins SL, Banasiewicz M. The descending septal artery in human, porcine, equine, ovine, bovine and canine hearts. A postmortem angiographic study. *Am Heart J*. 1961;62:247–259.
4. Taylor JR. The descending septal artery: its relation to the conduction system of the heart. *Arch Pathol Lab Med*. 1980;104(11):599–602.
5. Von Ludinghausen M, Ohmarch N. Right superior septal artery with “normal” right coronary and ectopic “early” aortic origin: a contribution to the vascular supply of the interventricular septum of the human heart. *Clin Anat*. 2001;14(5):312–319.

From the ¹Deborah Heart and Lung Institute, Browns Mills, New Jersey and ²NHL Municipal Medical College & Seth V.S. Hospital, Ahmedabad, India.

Disclosure: The authors have completed and returned the ICMJE Form for Disclosure of Potential Conflicts of Interest. The authors report no conflicts of interest regarding the content herein.

Manuscript submitted July 25, 2012, provisional acceptance given August 6, 2012, final version accepted August 13, 2012.

Address for correspondence: Kintur Sanghvi, MD, FACC, FSCAI, Deborah Heart & Lung Institute, 200 Trenton Road, Browns Mills, NJ 08015. Email: sanghvik@deborah.org

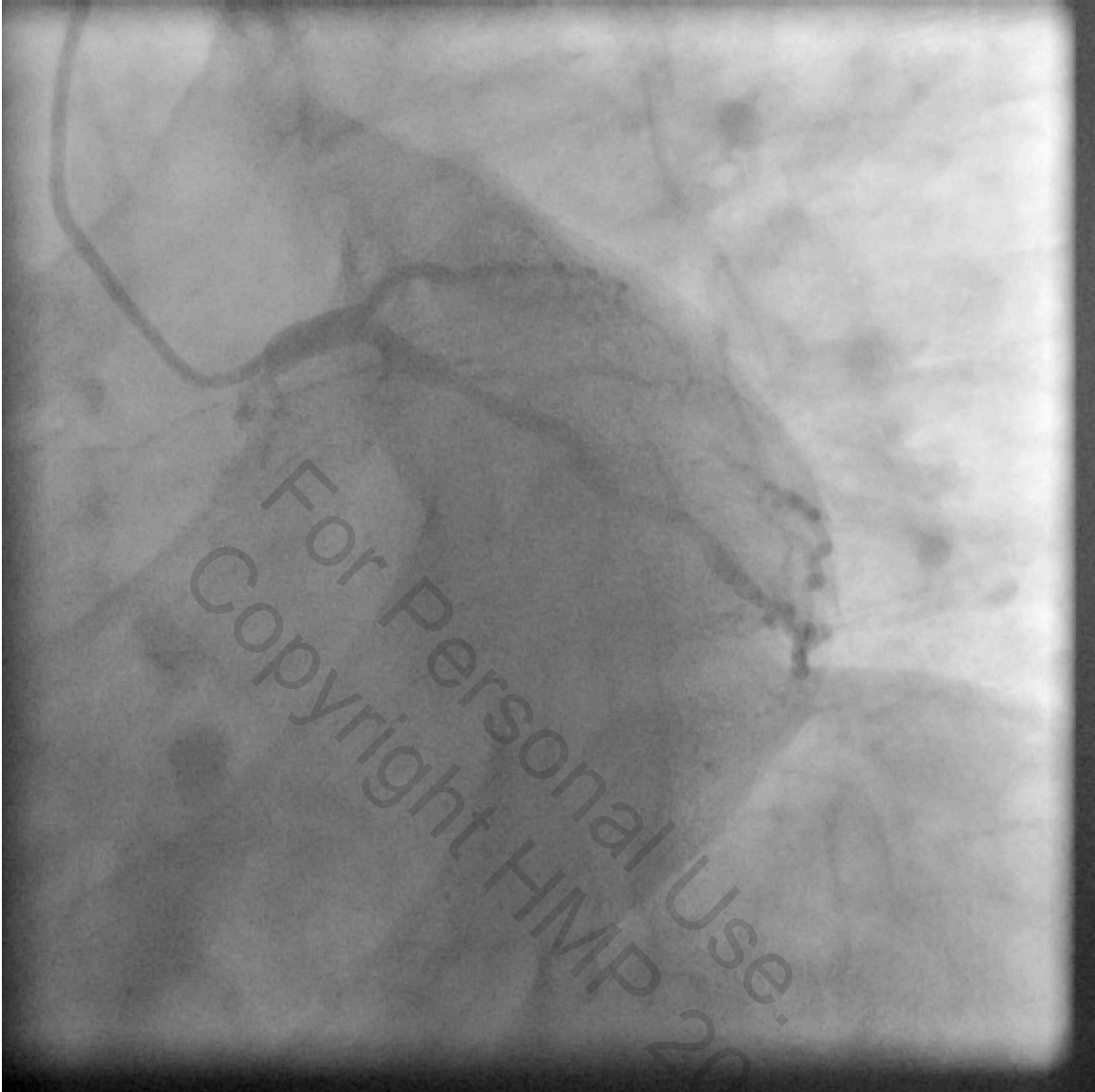

Figure 1. Left anterior oblique caudal view showing left main, left circumflex, and diagonal arteries as well as flush occlusion of the left anterior descending coronary artery.

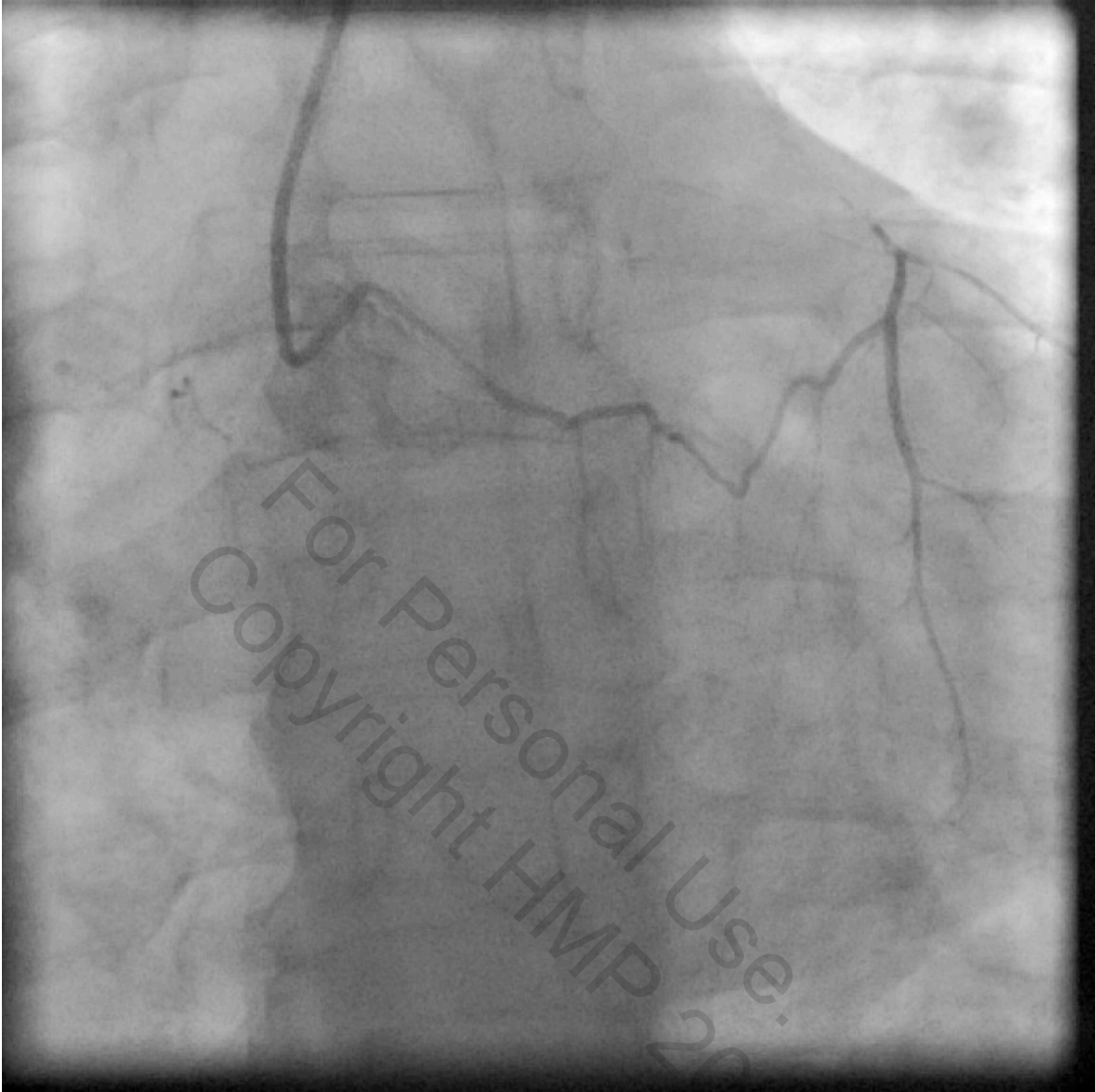


Figure 2. Selective cannulation of the descending septal artery in the right coronary cusp providing septal collaterals to the left anterior descending coronary artery.

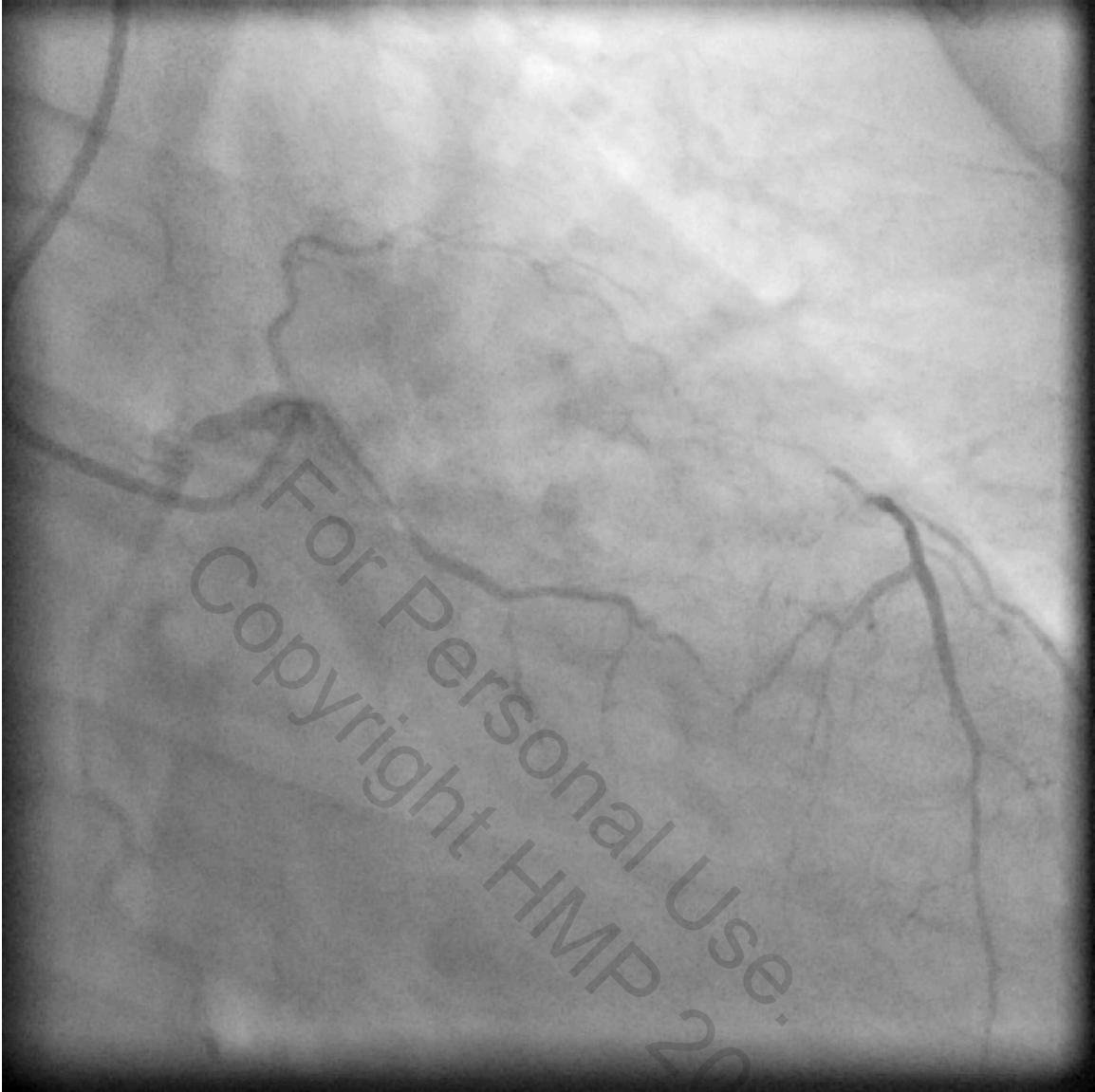


Figure 3. Selective cannulation of the descending septal artery and subselective filling of the right coronary artery showing: conus branch supplying faint collateral to the left anterior descending, descending septal artery filling the left anterior descending via septal collaterals, and the right coronary artery.

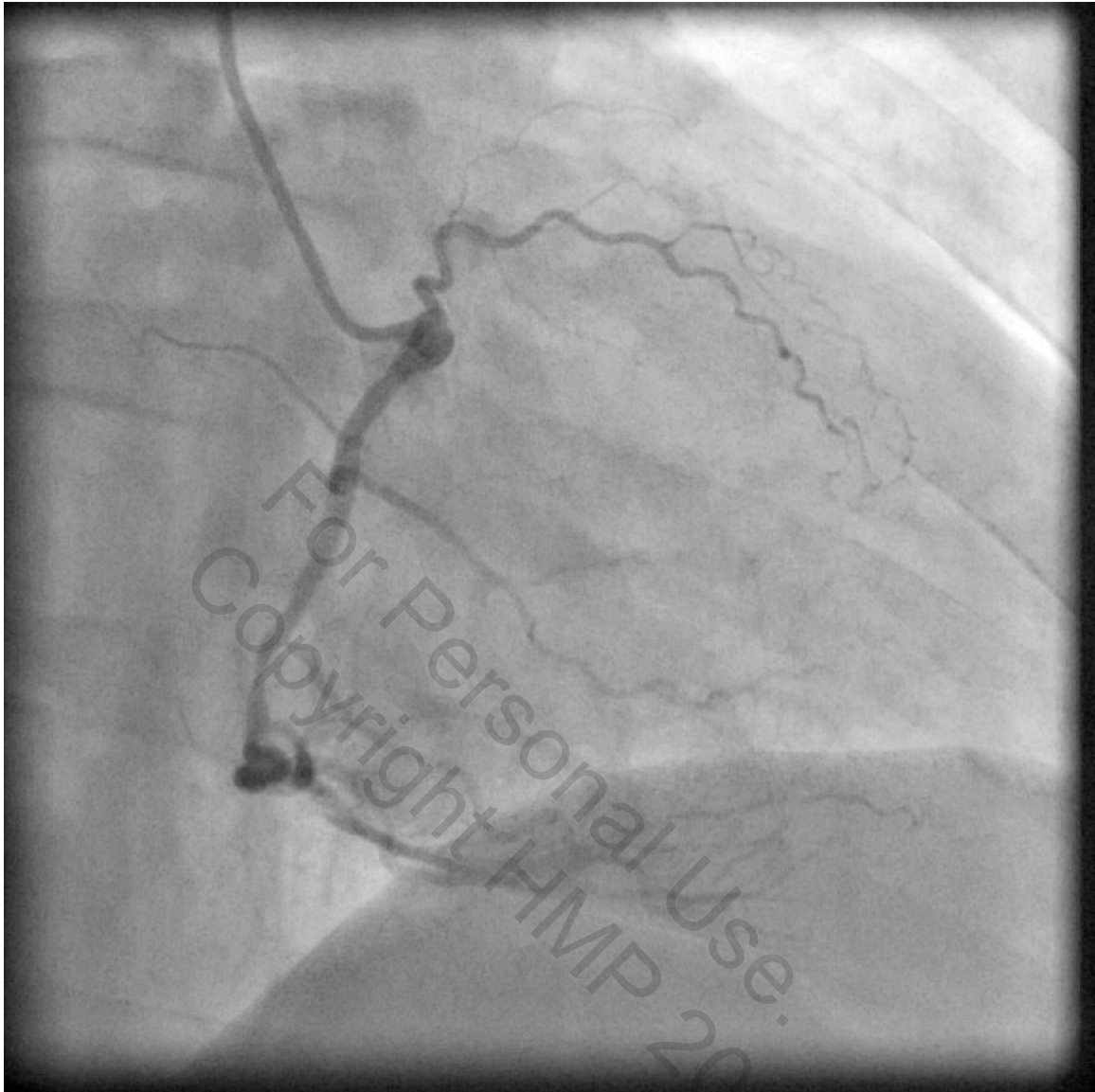


Figure 4. Selective angiograms of the right coronary artery in right anterior oblique view showing focal stenosis in the mid right coronary artery. The conus is seen with faint collateral to the left anterior descending coronary artery.