



Issue Date: November 2005, Posted On: 12/1/2005

Replacing Hopeless Retained Deciduous Teeth in Adults Utilizing Dental Implants: Concepts and Case Presentation

Michael Tischler, DDS



Hopeless retained deciduous teeth without permanent successors pose a restorative challenge for clinicians as well as certain clinical problems for patients. Compromised aesthetics, shifting of adjacent teeth, altered occlusion, and supereruption of teeth are examples of problems that can arise when a permanent tooth is congenitally missing. Mattheeuws, et al¹ reported that the mandibular second premolars are the permanent teeth most often congenitally missing, followed in prevalence by the maxillary lateral incisors and the maxillary second premolars. Larmour, et al² reported that in Caucasians the mandibular second premolars and maxillary lateral incisors were the teeth most frequently absent, while in Asians the mandibular incisors were the most frequently missing teeth.

The condition of having less than 6 congenitally missing teeth is termed hypodontia. Hypodontia is a multifactorial condition and in certain cases has been associated with a number of systemic conditions and dental anomalies.² The prevalence of hypodontia is reported to range from 2.6% to 11.3%, based mainly on radiographic studies. There is a 3:2 female-to-male ratio for hypodontia.² If one or a few permanent teeth are congenitally missing without any systemic disorders, this is considered to be an autosomally inherited dominant condition with varying gene expression and incomplete penetrance.³

While various treatment approaches for congenitally missing teeth have been proposed, outcome data pertaining to these treatment options are lacking.⁴ Replacement of a missing tooth with a dental implant offers specific advantages over other options for tooth replacement such as removable dentures or a fixed bridge.⁵ These advantages include preservation of the alveolar crest, no need to restore the adjacent teeth, and improved aesthetics and function. By understanding the principles of treatment planning, implant surgery, and implant restoration, a clinician can successfully replace a hopeless retained deciduous tooth with a dental implant.

This article will discuss the treatment planning and surgical and prosthetic principles for the replacement with implants of hopeless retained deciduous teeth. A case presentation will be used for illustration.

Treatment Planning

The literature supports keeping healthy retained deciduous teeth in adults when they are nonmobile and functioning.⁶ When a deciduous tooth is nonmobile, functioning, and meets a patient's aesthetic standards, there is justification for maintaining the tooth. The advantages to retaining a healthy deciduous tooth include the psychological benefits of a person keeping his or her own tooth and the ability of that tooth to maintain the surrounding bone and soft tissue.

However, once it is determined that a retained deciduous tooth is hopeless, then options for replacement must be evaluated. Severe mobility, extensive caries, root resorption, and fracture are reasons a deciduous tooth may not be able to be retained.

Treatment planning for replacement of a hopeless retained deciduous tooth involves a periodontal evaluation, determining the status of the adjacent teeth, radiographic evaluation (sometimes including a CT scan), diagnostic study models, taking a medical history, evaluation of prosthetic options, orthodontic evaluation, and assessment of the type of provisional restoration that will be required. The prosthetic outcome must be envisioned.

A CT scan can offer valuable information with regard to the available bone apical to a retained deciduous tooth. The vertical height and buccal/lingual width of remaining bone are the main determinants of soft-tissue support.⁷ This osseous support also determines if placement of a dental implant is feasible immediately after extraction of the deciduous tooth or if bone grafting is needed.

A CT scan also offers valuable information regarding availability of space, bone density, and the choice of implant size. Since retained deciduous teeth generally have short roots, the bone apical to the root can be seen on the CT scan. Due to the relationship of the deciduous tooth to the bone, often a radiographic stent is not needed for a CT scan, as the deciduous tooth offers a natural radiopaque marker.

Another important consideration is to determine the postsurgical position of the papillae and soft tissue. Performing a periodontal examination is critical. The attachment level of the adjacent teeth is an important factor in achieving papillae preservation after

tooth extraction.⁸

Prior to dental implant placement, the design and type of implant must be determined. Greater surface area will distribute stress on the implant, and this can be accomplished through utilization of a treated surface such as hydroxyapatite. Increased length, increased width, and using square-shaped threads will also increase the surface area of an implant, therefore resulting in reduced shear forces.⁹

As part of the treatment- planning process the clinician should also consider the many available dental implant systems so that choices can be made with respect to the prosthetic attachments available, the type of connection of the abutment, and other subtle differences in various systems that might affect the outcome of a case.

Surgical Principles

After comprehensive treatment planning, surgical placement of the dental implant can occur. In many cases when replacing deciduous teeth, flapless surgery can be accomplished due to the soft-tissue space maintenance that the deciduous tooth provided. A deciduous tooth often has a short root, yet the intact coronal aspect of the tooth supports the adjacent soft tissue until a dental implant can be placed. One of the most important initial steps in replacing a deciduous tooth with a dental implant is to extract the deciduous tooth atraumatically. The goal is to remove the tooth without removing any adjacent bone so there is sufficient bone for dental implant placement and support of the adjacent papillae. This atraumatic extraction can be accomplished through various methods, including forcep rotation, use of periostomes, and careful elevation.

As noted, retained deciduous teeth can offer the advantage of maintaining soft and hard tissue at the site. However, when a tooth is missing and there has been loss of bone at the edentulous area, bone grafting may be required followed by placement of the dental implant at a later date. Alternatively, bone grafting and implant placement may occur at the same visit.

A surgical guide based on information from the CT scan will direct the osteotomy away from adjacent teeth or implants. If a CT scan is not performed, multiple radiographs during the osteotomy sequence should be taken.

Correct spacing of a dental implant in proximity to another implant or natural teeth is important for papillae preservation. A minimum of 1.5 mm should be the distance between the implant and an adjacent tooth, and a minimum of 3 mm should be allowed in relation to an adjacent implant.¹⁰ If an implant is too close to another implant or tooth, subsequent bone loss could occur and the papillae could be lost.

Prosthetic Principles

Often, the presence of a deciduous tooth will preserve the bone and soft tissue, which allows immediate implant placement into the extraction site. If immediate dental implant placement is performed, the next decision to make is whether to place a provisional restoration on the implant or wait a period of time for increased implant stability. If the treatment plan includes a period of time between dental implant placement and attachment of a provisional restoration, then a healing cap can be placed to preserve the soft-tissue emergence profile.¹¹ If possible, an index impression should be made during surgery when an implant will not be immediately loaded. The index impression at the time of surgery allows a dental laboratory to prepare an abutment and create a laboratory-processed provisional restoration.¹²

If a bone graft is performed after extraction of a deciduous tooth, then an ovate pontic should be considered for papillae preservation.⁸

Case Presentation

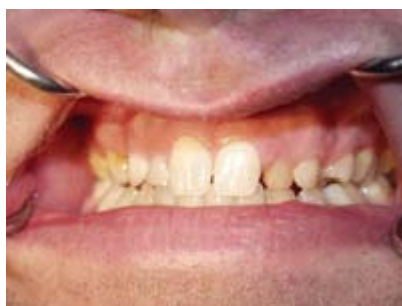

Figure 1. Patient at presentation with retained deciduous teeth in the anterior region.

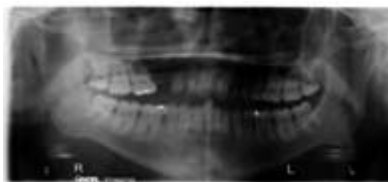

Figure 2. Panograph at initial visit demonstrating deciduous teeth without permanent successors.

A healthy 41-year-old male presented with retained deciduous teeth c, d, g, and h. These teeth did not have permanent successors. Deciduous tooth b was missing, as was its permanent successor (Figures 1 and 2). Teeth c, d, g, and h were mobile, and the patient was unhappy with his appearance.

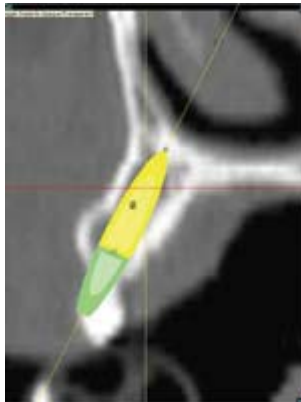


Figure 3. Image from Sim Plant CT program showing buccal/lingual positioning of the dental implant in the area of tooth b.

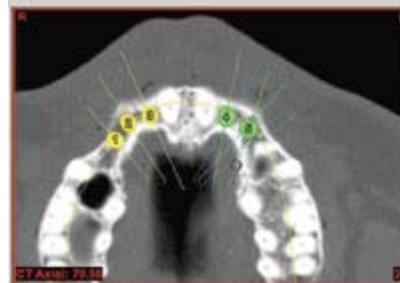


Figure 4. Axial view from Sim Plant CT program demonstrating planned position of the implants.

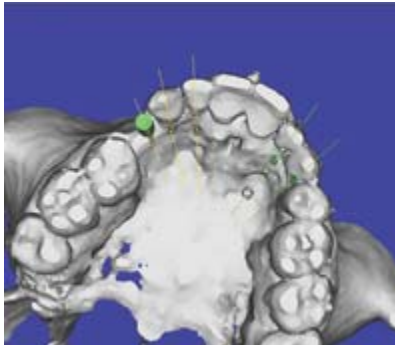


Figure 5. A 3-D view from Sim Plant Interactive CT program demonstrates planning of the case in relation to existing deciduous teeth.

The treatment plan consisted of replacement of the retained deciduous teeth and missing deciduous tooth b with a cement-retained fixed prosthesis supported by dental implants. A CT scan utilizing an interactive CT program (Sim Plant/Materialise) was used for planning implant placement (Figures 3 to 5).

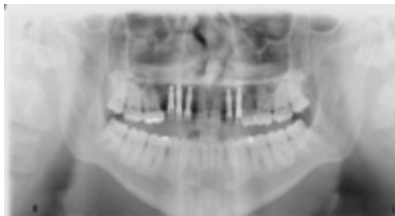

Figure 6. Panograph after implant placement.

After simple extraction of teeth c, d, g, and h, 3.5x12-mm external hex implants (BioHorizons) were placed in those positions and the b position (Figure 6). Flapless surgery was performed.

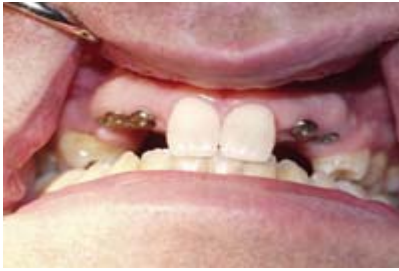

Figure 7. Healing caps in place allowing formation of emergence profile.

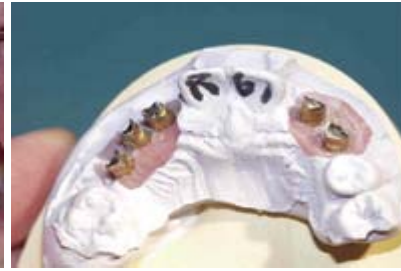

Figure 8. Laboratory model allowing preparation of stock BioHorizons abutments (BioHorizons).

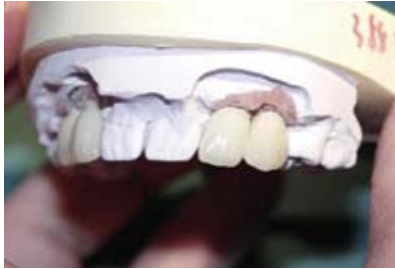

Figure 9. Laboratory model showing provisional restorations on abutments.

Healing caps were placed at the time of surgery, and a removable acrylic provisional prosthesis was placed for the 3-month healing period (Figure 7). Further, at the time of surgery, an index impression was taken and a laboratory model was fabricated so that the abutments could be prepared and fixed provisional restorations could be created (Figures 8 and 9).

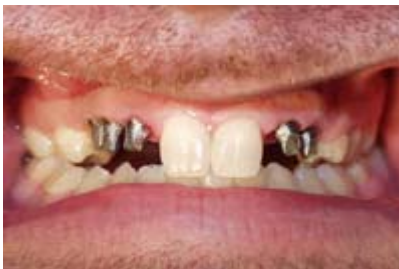

Figure 10. Laboratory-prepared abutments after placement.

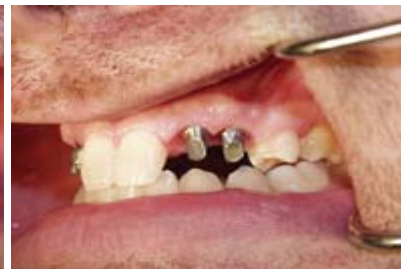

Figure 11. Close-up view of abutments. Note papillae formation.

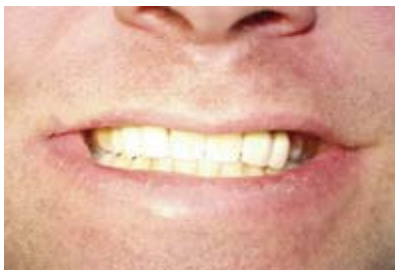

Figure 12. Delivery of laboratory-processed provisionals.

Three months after implant placement, the healing caps were removed and the laboratory-processed abutments and provisional restorations were placed in the mouth (Figures 10 to 12). The abutments were torqued to 33 Ncm.

A traditional closed-tray crown and bridge impression was made with polyvinyl siloxane, and a metal try-in of the frame was accomplished. The metal frame try-in allows the clinician to assess the marginal fit of the crowns and framework integrity before proceeding to porcelain baking (Figure 13). All crowns were splinted for increased stability.

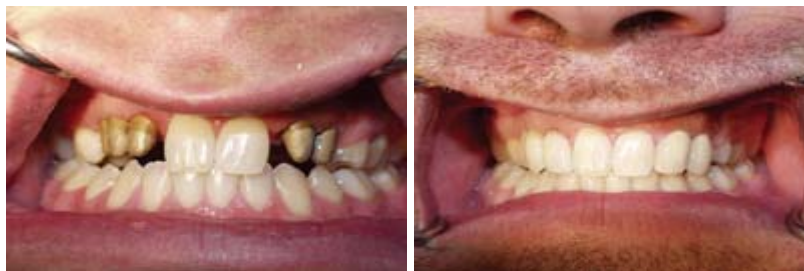

Figure 13. Metal frame try-in to check marginal integrity. **Figure 14.** Delivery of final prosthesis.

The final PFM crowns were cemented with ZOP cement (Flecks, Figure 14).

Discussion

The case described is interesting in that multiple permanent teeth were congenitally missing. There was no association with a systemic disease or condition. The planning and treatment approach demonstrate the principles that are appropriate for any number of hopeless retained deciduous teeth.

Multiple congenitally missing teeth (CMT) may be associated with certain skeletal and systemic conditions. Ben-Bassat, et al¹³ reported that in severe cases of CMT, the skeletodental pattern can be distinctive. This study of Israeli patients with multiple CMT found that the maxillary and mandibular basal bones were more retruded than in unaffected populations, but the intermaxillary relationship was normal. The study concluded that patients with multiple CMT, especially patients with missing incisors, demonstrate a characteristic skeletodental pattern.

Conditions that may be associated with CMT include congenital disorders such as Rieger syndrome, Mendelian inherited conditions such as incontinentia pigmenti, autosomal dominant conditions such as cherubism, autosomal recessive conditions such as Ellis-van Creveld syndrome, and X-linked inherited conditions such as focal dermal hypoplasia.¹⁴

Conclusion

By following sound treatment-planning principles, including a CT scan, dental implants can be predictably placed to replace hopeless retained deciduous teeth in adults. Maintenance of bone and soft tissue associated with retained deciduous teeth offers advantages for dental implant placement. This article has outlined the treatment planning, surgical principles, and prosthetic principles, and presented a case report for successful replacement of hopeless retained deciduous teeth with dental implants.

References

1. Mattheeuws N, Dermaut L, Martens G. Has hypodontia increased in Caucasians during the 20th century? A metaanalysis. *Eur J Orthod.* 2004;26:99-103.
2. Larmour CJ, Mossey PA, Thind BS, et al. Hypodontia: a retrospective review of prevalence and etiology. Part I. *Quintessence Int.* 2005;36:263-270.
3. Arte S, Nieminen P, Pirinen S, et al. Gene defect in hypodontia: exclusion of EGF, EGFR, and FGF-3 as candidate genes. *J Dent Res.* 1996;75:1346-1352.
4. Haselden K, Hobkirk JA, Goodman JR, et al. Root resorption in retained deciduous canine and molar teeth without permanent successors in patients with severe hypodontia. *Int J Paediatr Dent.* 2001;11:171-178.
5. Misch CE. The importance of dental implants. *Gen Dent.* 2001;49:38-45.
6. Sletten DW, Smith BM, Southard KA, et al. Retained deciduous mandibular molars in adults: a radiographic study of long-term changes. *Am J Orthod Dentofacial Orthop.* 2003;124:625-630.
7. Tischler M. Dental implants in the esthetic zone. Considerations for form and function. *N Y State Dent J.* 2004;70:22-26.

8. Spear FM. Maintenance of the interdental papilla following anterior tooth removal. *Pract Periodontics Aesthet Dent.* 1999;11:21-28.
 9. Steigenga JT, al-Shammari KF, Nociti FH, et al. Dental implant design and its relationship to long-term implant success. *Implant Dent.* 2003;12:306-317.
 10. Tarnow DP, Cho SC, Wallace SS. The effect of inter-implant distance on the height of inter-implant bone crest. *J Periodontol.* 2000;71:546-549.
 11. Tischler M. Dental implant placement in the maxillary anterior region: guidelines for aesthetic success. *Dent Today.* Mar 2005;24:72-76.
 12. Henry PJ, Tan AE, Uzawa S. Fit discrimination of implant-supported fixed partial dentures fabricated from implant level impressions made at stage I surgery. *J Prosthet Dent.* 1997;77:265-270.
 13. Ben-Bassat Y, Brin I. Skeletodental patterns in patients with multiple congenitally missing teeth. *Am J Orthod Dentofacial Orthop.* 2003;124:521-525.
 14. Hypodontia information. Diseases Database web site. Available at: www.diseasesdatabase.com/ddb29892.htm. Accessed September 22, 2005.
-

Dr. Tischler is a diplomate of the American Board of Oral Implant-ology/Implant Dentistry and the International Congress of Oral Implantologists, and a fellow of the American Academy of Implant Dentistry and the Academy of General Dentistry. He maintains a private practice in Woodstock, NY, and can be reached at mt@tischlerdental.com.

To comment on this article, visit the discussion board at dentistrytoday.com.



Continuing Education Test No. 71.3



After reading this article, the individual will learn:

• the clinical challenges associated with congenitally missing teeth, and
• the treatment planning, surgical, and prosthetic principles associated with replacing retained deciduous teeth with dental implants.

1. In Caucasians, the permanent tooth that is most commonly congenitally missing is the _____.

- a. maxillary second premolar
- b. mandibular second premolar
- c. mandibular lateral incisor
- d. mandibular first premolar

2. Treatment planning for replacement of a retained deciduous tooth includes _____.

- a. a periodontal evaluation
- b. noting the status of the adjacent teeth
- c. a CT scan
- d. all of the above

3. A CT scan can offer all of the following information except _____.

- a. the available bone apical to a retained deciduous tooth

- b. the available bone density
- c. the adjacent soft-tissue health
- d. information on the choice of the size of an implant to be used

4. Dental implant design considerations to increase the surface area of an implant include all of the following except _____.

- a. a treated surface such as hydroxyapatite
- b. a smooth titanium surface
- c. square-shaped threads
- d. increased width of an implant

5. Methods to extract a deciduous tooth atraumatically include all except _____.

- a. the use of forcep rotation
- b. the use of periotomes
- c. careful elevation
- d. a surgical bony purchase

6. The advantages of maintaining a healthy deciduous tooth include all of the following except _____.

- a. psychological benefits to the patient
- b. the ability to maintain surrounding bone
- c. the ability to maintain surrounding soft tissue
- d. decreased financial expense

7. Dental implants offer the following advantage(s) over other tooth replacement options:

- a. preservation of the alveolar crest.
- b. no need to involve adjacent teeth.
- c. improved aesthetics.
- d. all of the above.

8. Making an index impression at the time of surgery allows _____.

- a. the dental laboratory to prepare the abutment
- b. an assessment of the final, healed soft-tissue position
- c. the dental laboratory to finalize the crown margin on a permanent restoration
- d. the clinician to see the final, healed position of a dental implant

To submit Continuing Education answers, download the answer sheet in PDF format (click Download Now button below). Print the answer sheet, identify the article (this one is Test 71.3), place an X in the box corresponding to the answer you believe is correct, and mail to Dentistry Today Department of Continuing Education (complete address is on the answer sheet).