



Issue Date: March 2005, Posted On: 5/2/2005

Dental Implant Placement in the Maxillary Anterior Region: Guidelines for Aesthetic Success

Michael Tischler, DDS

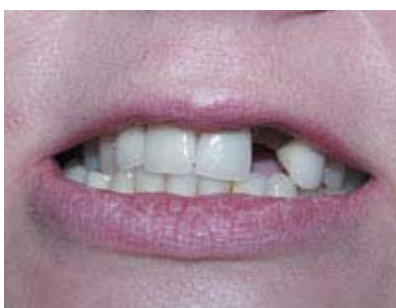

Figure 1. A 43-year-old female patient missing left lateral incisor.

The use of dental implants in the maxillary anterior region to replace missing teeth is a viable treatment option (Figure 1). There are many benefits of fixed dental implant-supported prosthetics versus traditional crown and bridge or removable tooth-borne prosthetics.¹ Maintenance of residual bone, ease of oral hygiene, increased longevity, and noninvolvement of adjacent teeth are a few advantages of using dental implants. In order to provide successful and aesthetic dental implant treatment, certain clinical parameters must be met. This is particularly true in the anterior maxilla, where the teeth and their supporting structures are readily visible.

Successful implant treatment to replace missing teeth in the anterior maxilla requires preoperative planning and a specific surgical plan, and ultimately prostheses are fabricated in consideration of function and soft-tissue support.² Technical expertise is also essential. Treatment planning must consider the final prosthetic result, so that implant surgery can be tailored to fulfill the preplanned objectives. Unless the position of the final prosthesis is visualized prior to surgery, the placement of the dental implants may not allow the desired end result to be achieved.³

Data that must be obtained to allow development of a proper treatment plan include probing depths and attachment levels for all remaining teeth, assessment of soft-tissue architecture, radiographic studies, study models, diagnostic wax-ups, and a comprehensive medical and dental history. Preoperative planning may indicate the need for an improved hard- and soft-tissue foundation prior to implant placement. Considerations for the creation of an ideal presurgical environment include atraumatic extractions, formation of papillae with ovate pontics, bone grafting with membranes, and connective tissue grafting.⁴ Ovate pontic placement after tooth extraction can create ideal papillae form prior to surgery, allowing for more predictable dental implant aesthetics.

The principles for maintaining a healthy biological width around natural teeth and implants should also be understood by the clinician. Provisional restoration of the treated area must also be considered. This last issue cannot be underestimated, since the provisional restoration is important for aesthetics and maintenance of hard- and soft-tissue form during an often lengthy treatment period.⁵

After a case has been planned, the implant surgery must be performed in consideration of ideal surgical technique, including conservative flap design, management of existing osseous architecture, correct spacing between adjacent implants or teeth, correct osteotomy preparation, and proper suturing techniques emphasizing primary closure.

Proper prosthetic concepts must also be followed to maximize aesthetics and function. The clinician must consider the time needed for implant integration and soft-tissue healing, creation of emergence profiles, occlusal forces in relationship to progressive loading, and occlusal forces on the final restoration.

This article will discuss the key concepts of treatment planning, implant surgery, and prosthetic rehabilitation needed to achieve aesthetic success in the maxillary anterior region.

Treatment planning

The first step in treatment planning for a dental implant case is to determine the desired end result, specifically the prosthetic outcome. When the prosthetic result is clearly visualized, a clinician can then take the appropriate earlier steps to satisfy the patient needs.⁶ This approach is particularly important in the maxillary anterior aesthetic zone. Planning involves interactive conversation with the patient, which includes educating the patient about available prosthetic options. Models, still images, and videotapes are often utilized to convey this information. This focus on the prosthetic end result is multifactorial, and includes discussion of issues such as finance, treatment time, and provisionalization during treatment.

A comprehensive medical history must be obtained to determine if the patient is a candidate for implant surgery.⁷ Any uncontrolled medical condition or pregnancy requires a delay in treatment, consultation with the patient's physician, and appropriate follow-up. Habits such as smoking, alcohol use, or drug use should be addressed and taken into consideration prior to initiating treatment.

Recording and consideration of occlusal factors are essential. Bruxism, parafunctional activity, muscular dynamics, as well as tooth mobility should be taken into consideration.⁸ Mobile teeth adjacent to the implants can compromise an implant-based restoration due to the lack of occlusal support. Study models should be taken to assess the occlusal dynamics of the patient and also provide legal documentation. Study models can also offer information on the position of a tooth or teeth that might require orthodontic movement in order to create the correct spacing for implant placement. Radiographic analysis via a panoramic film, periapical films, and computerized tomography (CT) provide critical information pertaining to the osseous architecture and tooth position. CT is especially helpful for treatment planning in a 3-D perspective⁹ (Figure 2).

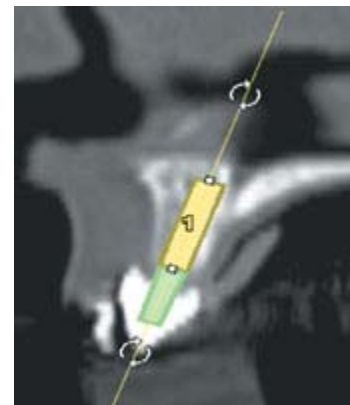


Figure 2. Interactive CT imaging to determine tooth position with respect to available osseous architecture.

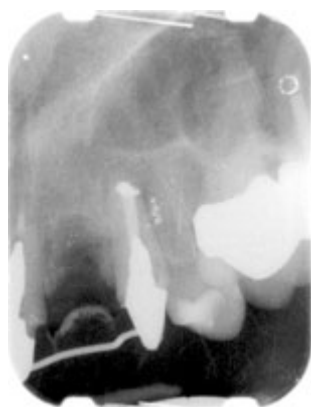

Figure 3. Periapical

Often, radiopaque guide stents are used with a CT scan to define tooth position better. Observing the final tooth position in relation to the existing osseous architecture allows decisions to be reached with respect to the need for osseous grafting. This prosthetic relationship on a CT scan also may help determine if a removable prosthesis is needed to support the maxillary lip. If a large discrepancy on a CT exists between the final tooth position and the existing bone, then lip support via a denture flange may be indicated. The existing osseous architecture visualized on a CT scan can also indicate soft-tissue support. This support is essential in the aesthetic zone, since the presence of papillae will be dictated in part by the osseous support around a dental implant as well as by the distance between implants.¹⁸ Tarnow has suggested that unless there is a distance of 5 mm or less between the osseous crest of bone and the interproximal prosthetic contact point, papillae formation between crowns will be compromised.¹¹ Therefore, it may be necessary to perform a bone graft prior to implant placement in order to achieve a more predictable aesthetic result (Figure 3).

radiograph indicating need for bone grafting prior to implant placement. Bone will support adjacent soft tissue and implant.

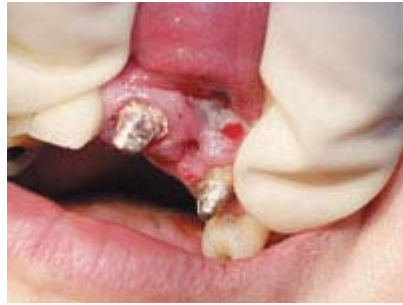

Figure 4. Three weeks postextraction of No. 10. Clinical evidence of missing buccal plate. Bone grafting required prior to dental implant placement.

A CT scan can also show the status of the buccal plate of bone in an edentulous area. This information is critical and influences many subsequent steps that might be needed to obtain an ideal aesthetic result. If the buccal plate is absent, then bone grafting will be needed prior to implant placement (Figure 4). A successful graft will provide the necessary osseous support for both implant stability and soft-tissue aesthetics.

The clinical examination provides information that is critical to the success of dental implant treatment. The existing soft tissue must be examined in relationship to the amount of keratinized tissue and periodontal parameters of the remaining teeth. Tissue that is thin and not well keratinized is prone to recession, and connective tissue grafting may be needed to avoid this problem.¹² Periodontal parameters help define the

osseous support for adjacent teeth. This is especially important with respect to predicting papillae formation between teeth and between a tooth and an implant. Documentation of the free gingival margin is important for determining the need for grafting or crown lengthening. The clinical record also provides the necessary medical-legal documentation.

The clinical examination will identify the presence of infection in the oral cavity. The presence of an acute infection is a contraindication to bone grafting or dental implant placement. The infection must be treated and resolved prior to surgery. There are factors to consider when placing a dental implant in an extraction site. There must be adequate osseous support for the implant and the surrounding soft tissues. The preservation of the osseous architecture begins with an atraumatic extraction technique and is an important step toward a favorable aesthetic outcome. The use of periostomes, forcep rotation, and orthodontic extrusion are some of the techniques utilized to extract a tooth while preserving the surrounding osseous housing. The presence of fully circumferential walls of bone is important for osseous support of a dental implant and to contain graft material if a bone graft is needed.¹³ If a tooth is extracted and a bone graft is needed, the presence of infection is a good reason to delay bone grafting for 2 to 3 weeks. If grafting an extraction site is delayed for 2 to 3 weeks, it is important to form the papillae with an ovate-shaped pontic. This can be done with a bonded tooth, pontic, or a stable removable appliance. Failure to support adjacent papillae soon after an extraction could create long-term aesthetic compromises. Further, delaying the bone graft will favor primary closure over the graft site.

Implant placement

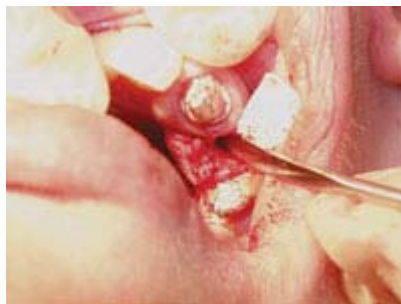

Figure 5. Bone grafting of extraction site of No. 10 utilizing a resorbable membrane. A conservative flap procedure was used to preserve the blood supply.

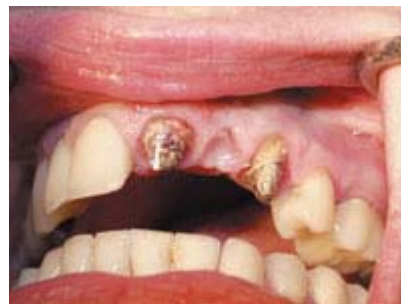

Figure 6. No. 10 area prior to implant placement, correct form of hard and soft tissue from previous graft.

The correct surgical placement of a dental implant is mandatory to obtain the ideal aesthetic result. Only through proper treatment planning can the correct position and number of implants be determined. Before surgical placement of a dental implant, the adequate hard and soft tissue must be available. If either hard or soft tissue is deficient, then grafting must occur prior to surgical placement of the implant. If grafting is to occur, then a conservative flap approach to preserve the vascular supply should be

considered (Figure 5). As noted, the interproximal osseous height should be within 5 mm of the proposed contact point, and adequate soft tissue should be present prior to surgical placement of the implants (Figure 6). Often, ovate pontics are utilized to form the soft-tissue bed prior to implant placement. An ovate pontic shape can be prepared through a provisional restoration or through tissue-sculpting techniques. The advantages of an ovate pontic are numerous and include improved oral hygiene and aesthetics.¹⁴

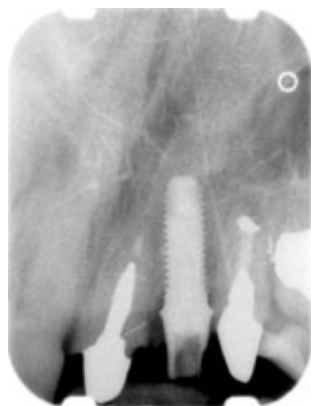

Figure 7. Correct spacing of dental implant to adjacent teeth allows for osseous support of interdental papillae.

The correct spacing between dental implants and/or natural teeth is an important consideration. Allowing a minimum of 3 mm between dental implants and 1.5 mm between adjacent teeth and a dental implant will provide adequate interproximal bone and an adequate blood supply.¹⁵ When adequate bone and an adequate blood supply are present, the soft tissue of the papillae can be maintained (Figure 7).

During preparation of the osteotomy, care must be taken not to create excessive heat, which can lead to necrosis of bone. A bur speed of 2,500 rpm, sharp osteotomy burs, copious irrigation, and sequential preparation of the osteotomy site can help reduce iatrogenic effects on bone during osteotomy preparation.¹⁶ In less dense bone, osteotomes and other bone manipulation techniques can be used in implant placement. Osteotomes can compress bone that is less dense, creating both an osteotomy preparation and increased density of the bone. It is also essential that adequate bone buccal to the dental implant is present. Often the dental implant is placed in a slightly lingual direction so that bone is present to the buccal of the implant. This aids in implant stability and soft-tissue coverage. Therefore, preoperative diagnosis and planning is essential. Further, if a mucoperiosteal flap is raised for osteotomy preparation, maintenance of the blood supply must be considered. Papillae-sparing incisions and broad-based, full-thickness flaps minimize aesthetic problems (Figure 8). Suturing techniques that ensure primary closure and a stable tissue position are important.

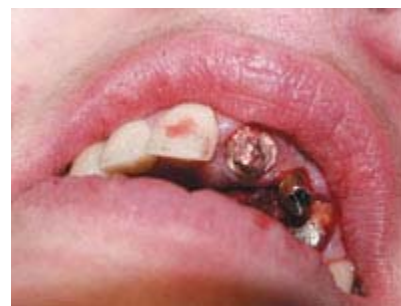

Figure 8. Conservative flap during dental implant placement in anterior maxilla preserves the blood supply.

Implant placement that minimizes angulation will re-duce off-load forces on the implants. With correct occlusal loading on an implant, bone and soft tissue can be maintained. Again, this is a result of correct pre-surgical planning.

Prior to implant placement, a decision must be made to submerge the implant or leave it exposed. At times this decision is modified at the time of surgery. A submerged implant requires uncovering after osteointegration. An implant is usually left submerged in less mineralized bone, when bone grafting is needed at the time of surgery, or if the forces on a provisional restoration would overload the implant. An advantage to leaving an implant exposed with a transmucosal extension (healing abutment) is the ability of the surrounding soft tissue to heal around the abutment and create an emergence profile.

Prosthetic Rehabilitation

Restoration is the last stage in this sequence. Improper restoration of a dental implant can negate good pretreatment planning and good surgical technique. If a dental implant is submerged, the restorative process begins following uncovering. In the anterior maxilla, there are advantages to uncovering a dental implant with a tissue punch versus a small mucoperiosteal flap. The main advantage is preservation of the blood supply and the adjacent papillae. If a flap is utilized to uncover a dental implant, papillae-sparing incisions and periodontal plastic surgical techniques should be utilized to aid with aesthetics (Figure 9).

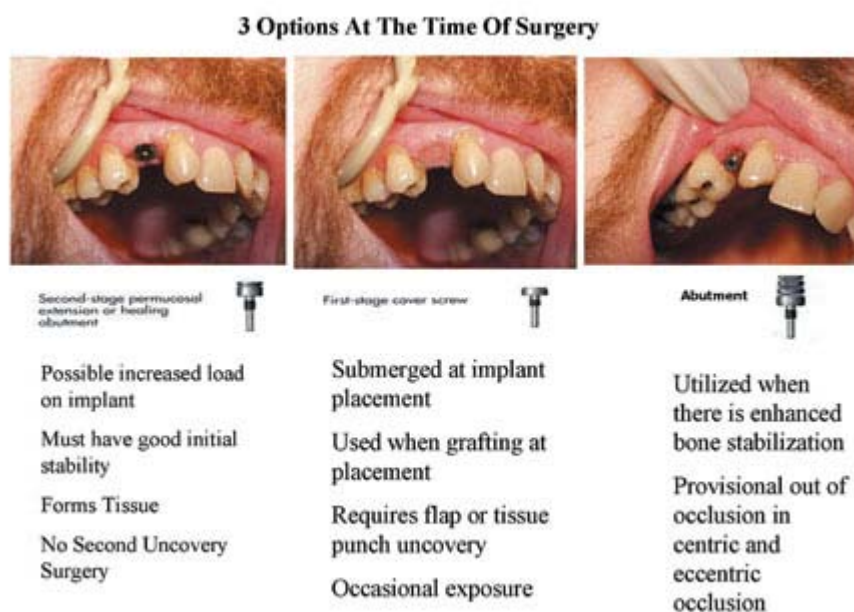


Figure 10. Three options at the time of surgical implant placement.

The concept of emergence profile is particularly important when treating the maxillary anterior region. The emergence profile can be obtained 3 different ways¹⁷ (Figure 10). One way is for the surrounding soft tissue to form around the healing abutment. The second is to sculpt the tissue around an implant so that the implant abutment creates the tissue form. This can be accomplished with a custom abutment at either the first stage (surgery) or second stage (uncovering). If an abutment is utilized to create the emergence profile at the first stage, then criteria for immediate loading must be considered. The third way to create the emergence profile is to allow the tissue to form around a provisional restoration. This can be done following first- or second-stage surgery either with an ovate pontic or a cemented restoration.

A general rule is to wait 2 to 3 weeks after implant uncovering before taking a final impression. This allows time for the emergence profile to form (Figure 11). A cement-

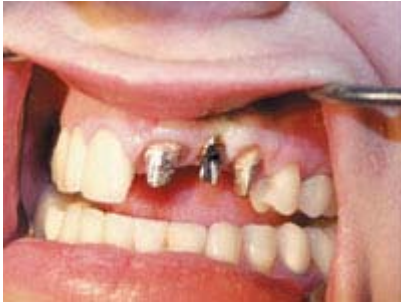

Figure 11. Two weeks after dental implant uncovering, ready for final impression.

retained fixed prosthesis should be considered. The advantages of a cement-retained prosthesis versus a screw-retained prosthesis include fewer components, no loosening of the screws, reduced occurrence of porcelain breakage in areas of occlusal contact, and less shear force on multiunit prostheses.¹⁸ The choice of an implant abutment is determined in part during presurgical planning. If a case is planned ideally, a straight abutment with an aesthetic margin can be used. If bone or soft tissue is inadequate, an angled abutment will likely be needed. The use of an angled abutment creates potentially detrimental forces on an implant and should be avoided if possible. If adequate keratinized tissue is present, margins that resist recession are ideal. Following the guidelines outlined in the article, the final prosthesis of the case presented is shown (Figure 12).

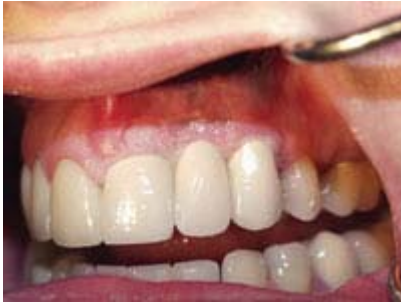

Figure 12. Final restoration of No. 10.

Conclusion

Placing dental implants in the maxillary anterior region requires precise planning, surgery, and prosthetic treatment. This article has illustrated the steps needed to create ideal aesthetics in the maxillary anterior region. Rigorous treatment planning allows the implant surgeon, working with the restorative dentist, to select location, angulation, and spacing of dental implants to achieve ideal aesthetics. Treatment planning also dictates the necessity for hard- and soft-tissue grafting, which is often crucial for an ideal aesthetic result.

Further, the prosthetic restoration of a dental implant must be ideal to achieve the desired aesthetic result. This article has discussed the importance of a comprehensive and interdisciplinary approach to treatment planning, surgery, and restoration of dental implants in the maxillary anterior region of the mouth.

References

1. Misch CE. The importance of dental implants. *Gen Dent.* 2001;49:38-45.
2. Tischler M. Dental implants in the esthetic zone. Considerations for form and function. *N Y State Dent J.* 2004;70:22-26.
3. Kopp KC, Koslow AH, Abdo OS. Predictable implant placement with a diagnostic/surgical template and advanced radiographic imaging. *J Prosthet Dent.* 2003;89:611-615.
4. Kan JY, Rungcharassaeng K. Site development for anterior single implant esthetics: the dentulous site. *Compend Contin Educ Dent.* 2001;22:221-232.
5. Schweikert E. Successful full-mouth reconstruction with laboratory-fabricated provisionals. *Dent Today.* Apr 1995;14:80-85.
6. Zitzmann NU, Marinello CP. Treatment plan for restoring the edentulous maxilla with implant-supported restorations: removable overdenture versus fixed partial denture design. *J Prosthet Dent.* 1999;82:188-196.
7. Barbosa F. Patient selection for dental implants. Part 1: data gathering and diagnosis. *J Indiana Dent Assoc.* 2000;79:8-11.
8. Jemt T, Lundquist S, Hedegard B. Group function or canine protection. *J Prosthet Dent.* 2004;91:403-408.

9. Kraut RA. Interactive CT diagnostics, planning and preparation for dental implants. *Implant Dent.* 1998;7:19-25.
10. Salama H, Salama MA, Garber D, et al. The interproximal height of bone: a guidepost to predictable aesthetic strategies and soft tissue contours in anterior tooth replacement. *Pract Periodontics Aesthet Dent.* 1998;10:1131-1142.
11. Tarnow DP, Magner AW, Fletcher P. The effect of distance from the contact point to the crest of bone on the presence or absence of the interproximal dental papilla. *J Periodontol.* 1992;63:995-996.
12. Marquez IC. The role of keratinized tissue and attached gingiva in maintaining periodontal/peri-implant health. *Gen Dent.* 2004;52:74-79.
13. Tischler M. Multi-modality anterior extraction site grafting. Increased predictability for aesthetics. *Dent Today.* 2003;22:94-98.
14. Miller MB. Ovate pontics: the natural tooth replacement. *Pract Periodontics Aesthet Dent.* 1996;8:140.
15. Tarnow DP, Cho SC, Wallace SS. The effect of inter-implant distance on the height of inter-implant bone crest. *J Periodontol.* 2000;71:546-549.
16. Sharawy M, Misch CE, Weller N, et al. Heat generation during implant drilling: the significance of motor speed. *J Oral Maxillofac Surg.* 2002;60:1160-1169.
17. Touati B, Guez G, Saadoun A. Aesthetic soft tissue integration and optimized emergence profile: provisionalization and customized impression coping. *Pract Periodontics Aesthet Dent.* 1999;11:305-316.
18. Singer A, Serfaty V. Cement-retained implant-supported fixed partial dentures: a 6-month to 3-year follow-up. *Int J Oral Maxillofac Implants.* 1996;11:645-649.

Dr. Tischler maintains a private practice in Woodstock, NY. He is a diplomate of the International Congress of Oral Implantologists and the American Board of Oral Implantology/Implant Dentistry, a fellow of the Misch International Implant Institute and the Academy of General Dentistry, and an associate fellow of the American Academy of Implant Dentistry. He can be reached at (845) 679-3706 or by visiting tischlerdental.com.

To comment on this article, visit the discussion board at dentistrytoday.com.

Continuing Education Test No. 63.3

After reading this article, the individual will learn:

• the principles that allow for aesthetic success when placing dental implants in the anterior maxilla.

• the importance of correctly spacing dental implants for maintenance of bone and associated papillae.

1. Which of the following is not a step in treatment planning for an implant in the maxillary anterior region?

- a. a comprehensive medical history
- b. study models for analysis of the patient's occlusion
- c. utilization of radiographic guide stents
- d. the use of an MRI to gauge the hard-tissue/soft-tissue interface

2. What is the minimal recommended spacing between dental implants?

- a. 3 mm
- b. 2 mm
- c. the width of the implant being used
- d. the equivalent of the biological width

3. Which is (are) the methods mentioned to avoid overheating bone during osteotomy preparation?

- a. a bur speed of 2,500 rpm
- b. utilization of copious irrigation
- c. sequential preparation of the osteotomy site
- d. all of the above

4. When should an implant be left submerged at placement?

- a. in less mineralized bone
- b. in highly mineralized bone
- c. when there are minimal forces from a provisional restoration on an implant

- d. when an emergence profile must be formed about a healing abutment

5. Which is not an advantage of cement-retained restorations?

- a. less screw loosening
- b. fewer components
- c. increased porcelain fracture
- d. less shear forces on a multiunit prosthesis

6. The technique(s) to preserve bone during tooth extraction is (are)?

- a. the use of periostomes
- b. orthodontic extrusion
- c. forcep rotation
- d. all of the above

7. Which is a contraindication to implant surgery?

- a. alcohol use
- b. smoking
- c. drug use
- d. pregnancy

8. The emergence profile can be formed in which way(s)?

- a. with a healing abutment
- b. with a provisional restoration
- c. with a custom abutment
- d. all of the above

To submit Continuing Education answers, download the answer sheet in PDF format (click Download Now button below). Print the answer sheet, identify the article (this one is Test 63.3), place an X in the box corresponding to the answer you believe is correct, and mail to Dentistry Today Department of Continuing Education (complete address is on the answer sheet).