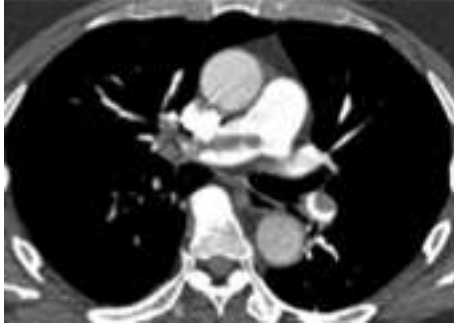

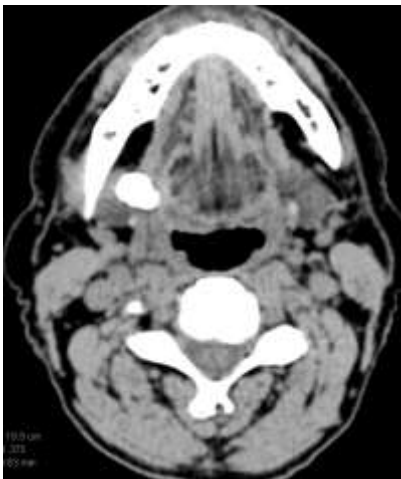Correlative imaging.

1. What is expected on a VQ scan of this patient?



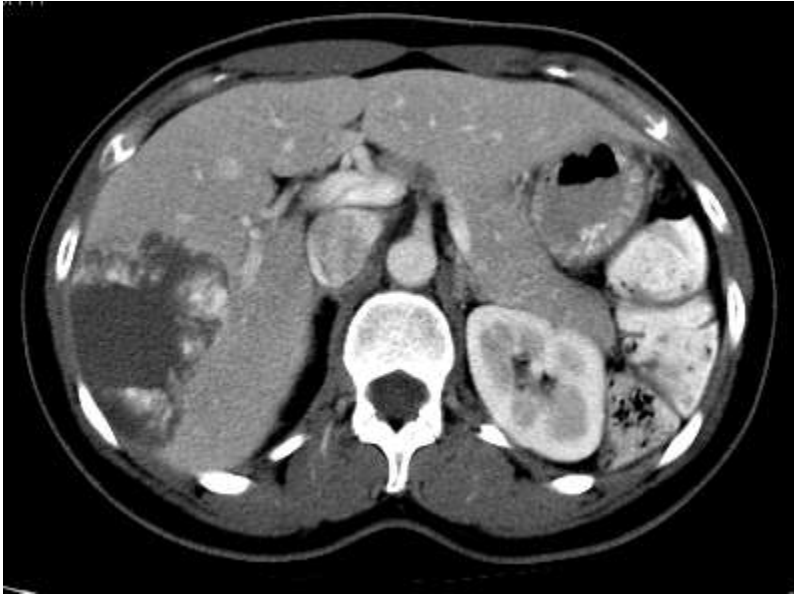- a. normal
- b. bilateral multifocal perfusion defects
- c. bilateral multifocal ventilation defects
- d. unilateral multifocal perfusion defects

2. The companion CT scan (bone window) of PET/CT in a patient with colon cancer is shown below. What is the diagnosis?



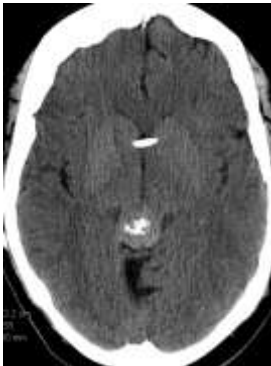- a. mucinous metastasis
- b. sialolith
- c. ranula
- d. volume average of left greater cornu of hyoid

3. For proper evaluation of this cystic lesion with peripheral enhancement in the right lobe of the liver, the best radiotracer would be



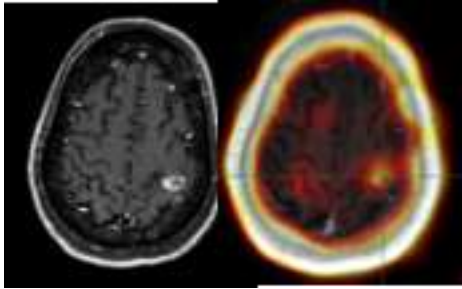
- a. ^{99m}Tc -labelled Mebrofenin
- b. ^{99m}Tc sulfur colloid scan
- c. ^{99m}Tc RBC scan
- d. ^{99m}Tc -HMPAO WBC scan

4. You are evaluating CT scan of PET CT of a patient with ovarian cancer. She had this known tumor for which a shunt surgery was done in the past. What is the likely diagnosis of this tumor?



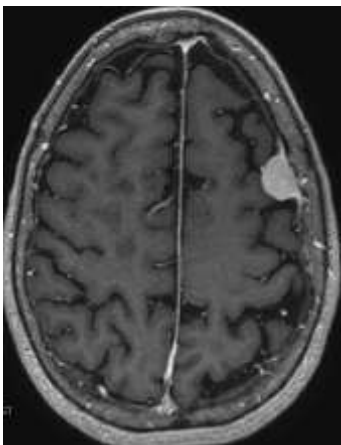
- a. glioblastoma multiforme
- b. cavernoma
- c. pilocytic astrocytoma
- d. 3rd ventricular choroid calcification

5. In a HIV positive patient with seizure MRI and ^{201}Tl scan are shown below. What is the diagnosis?



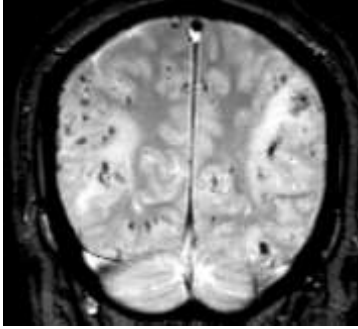
- a. lymphoma
- b. toxoplasmosis
- c. PML
- d. HIV encephalopathy

6. This intensely enhancing tumor (with enhancement of the adjacent dura mater) showed high uptake of ¹¹¹In-Pentetreotide. What is the likely diagnosis of the tumor?



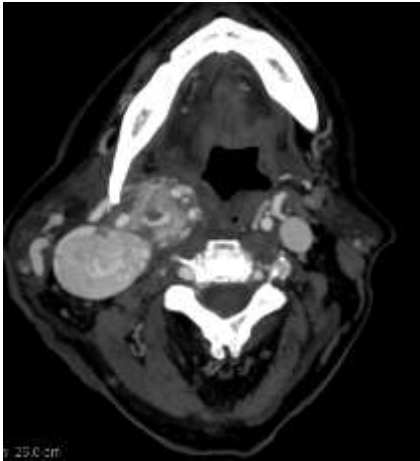
- a. metastasis
- b. meningioma
- c. glioma
- d. paraganglioma

7. 72 year old man is being evaluated for dementia. The gradient echo MRI revealed the following findings. What is the diagnosis?



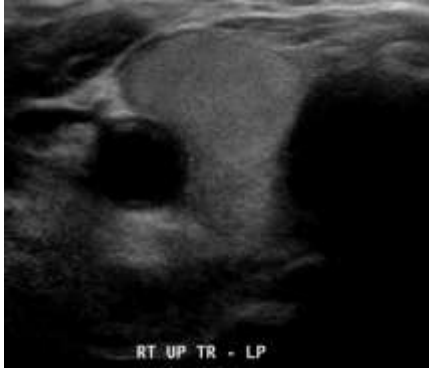- a. amyloid angiopathy
- b. frontotemporal dementia
- c. Alzheimer's disease
- d. corticobasal degeneration

8. This hypervascular tumor showed intense uptake on ¹¹¹In Pentreotide scan. What is the likely diagnosis of this tumor?



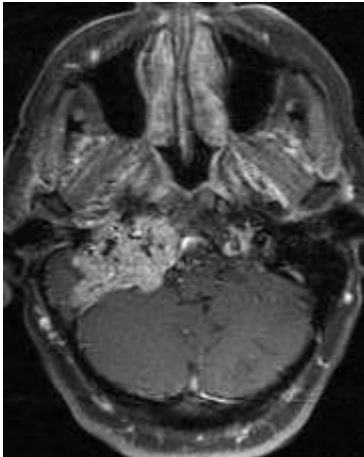
- a. schwannoma
- b. paraganglioma
- c. metastatic lymph node
- d. rhabdomyosarcoma

9. Forty-five year old asymptomatic male patient had this mass at the superior pole of the right lobe of the thyroid gland, which is positive on sestamibi scan. Which of the following is true regarding treatment?



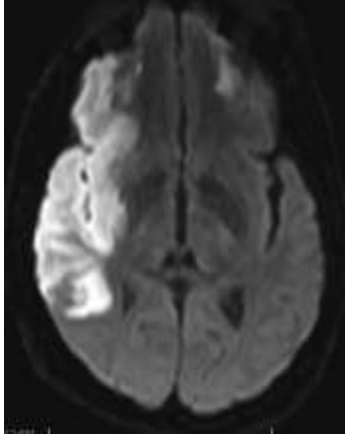
- a. surgery
- b. I131 therapy
- c. I131 and surgery
- d. Follow up at a regular interval.

10. Where is this tumor located?



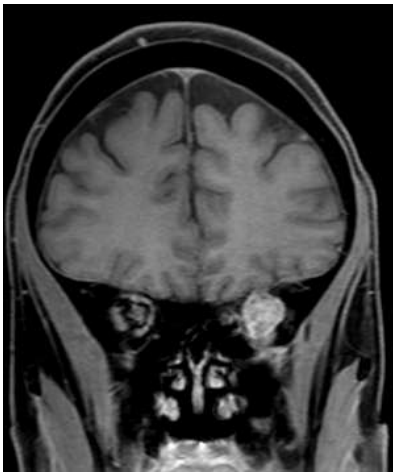
- a. right internal auditory canal
- b. right petrous apex
- c. right jugular fossa
- d. right Meckel cave

11. Sixty-five year old man presented with left sided weakness. The diffusion weighted imaging demonstrated the following. If a cerebral perfusion study is done what would be the findings?



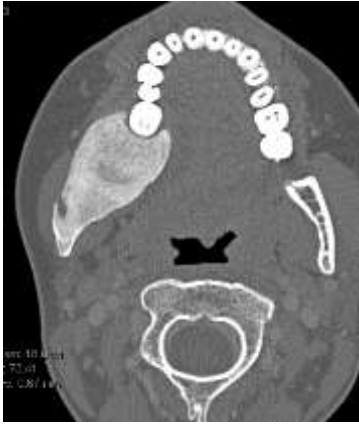- a. normal
- b. increased perfusion
- c. decreased perfusion
- d. insufficient data for this prediction.

12. You are evaluating a follow-up PET CT scan of a fifty-nine-year old patient with history of adenoid cystic carcinoma of the left lacrimal gland status post left orbital exenteration. You see intense uptake at the left orbital apex, which was normal in the prior scan. For better localization you referred to the previously obtained contrast enhanced MRI. What is the likely diagnosis?



- a. perineural tumor spread along the v1 branch of trigeminal nerve
- b. perineural tumor spread along the v3 branch of trigeminal nerve
- c. left optic nerve sheath meningioma
- d. low grade optic nerve glioma

13. This slowly growing right mandibular lesion of a 22-year old female is intensely hot on bone scan. What is the diagnosis?



- a. dentigerous cyst
- b. Paget's disease
- c. fibrous dysplasia
- d. osteosarcoma

Correlative Imaging Answers

1. B
2. B
3. C
4. B
5. A
6. B
7. A
8. B
9. A
10. C
11. C
12. A
13. C